

Flexible solutions for **complex** wound reconstruction

Table of contents

| | |
|--|---|
| Preparation of wound bed and application of MatriDerm® | 4 |
| Decision Tree | 5 |

Burns

| | |
|--|----|
| Hand scar revision after burn, <i>L. Kamolz, MD, Graz, Austria</i> | 6 |
| Pediatric scald burn, <i>J. Lee, MD, Seoul, S. Korea</i> | 8 |
| Massive scar contracture on flank, <i>J. Grünert, MD, St. Gallen, Switzerland</i> | 10 |
| Revision surgery of burn scar at the lower limb, <i>A. Modarressi, MD, Geneva, Switzerland</i> | 12 |
| Flame burn on chest and neck, <i>E. Dantzer, Toulon, France</i> | 14 |

Trauma

| | |
|---|----|
| Degloving of the forearm in a work accident, <i>M. Kerl, MD, Graz, Austria, Epigard by Biovision GmbH</i> | 16 |
| Degloving injury at lower leg, <i>M. Öhlbauer, MD, Murnau, Germany</i> | 18 |
| Crush trauma by a school bus, <i>M. Öhlbauer, B. Wallner and M. Militz, MD, Murnau, Germany</i> | 20 |
| Avulsion injury at the foot with exposed Achilles tendon, <i>U. Graf, MD, Zurich, Switzerland</i> | 22 |
| Infected dog bite at the dorsum of the hand, <i>U. Hug, MD, Luzern, Switzerland</i> | 24 |
| Deglovement instep and plantar regions after motor-bike injury, <i>M. Öhlbauer, B. Wallner and M. Militz, MD, Murnau, Germany</i> | 26 |
| Circular saw injury, <i>L. Mathys, MD, Bern, Switzerland</i> | 28 |
| Trauma by car accident, <i>D. F. Kalbermatten, MD, Basel, Switzerland</i> | 30 |
| Necrotizing Fasciitis of abdominal wall, <i>I. Younis, MBBCh, MRCS (Eng), MSc, FRCS (Plast), London, UK</i> | 32 |
| Necrotizing Fasciitis of lower leg, <i>I. Younis, MBBCh, MRCS (Eng), MSc, FRCS (Plast), London, UK</i> | 34 |

Chronic Wounds

| | |
|--|----|
| Chronic venous ulcer with 3.5 years follow-up, <i>F. Tostes, MD, Rio Grande do Sul, Brazil; V.A.C. therapy and GranuFoam by Kinetic Concept, Inc (KCI)</i> | 36 |
| Diabetic foot syndrome with gangrene, <i>D. Luedi, MD, Langenthal, Switzerland</i> | 38 |
| Chronic diabetic ulcer at clubfoot, <i>H. Mössner, MD, Salzburg, Austria; Medihoney by Derma Sciences, Inc; Hyiodine by Contipro Group s.r.o.</i> | 40 |
| Chronic mixed ulcer in diabetic patient, <i>M. Öhlbauer, MD, Murnau, Germany</i> | 42 |
| Large pressure ulcer after an ischaemic stroke, <i>M. Öhlbauer, MD, Murnau, Germany</i> | 44 |

Cancer Excision

| | |
|--|----|
| Large squamous cell carcinoma, <i>D. Luedi, MD, Langenthal, Switzerland</i> | 46 |
| Basal cell carcinoma excision in face, <i>N. Lilgenau, MD, Vienna, Austria</i> | 48 |
| Carcinoma resection in 97-year-old patient, <i>V. Wedler, MD, Frauenfeld, Switzerland</i> | 50 |
| Melanoma on the nasal ridge, <i>M. Öhlbauer, MD, Murnau, Germany</i> | 52 |
| Malignant melanoma on plantar foot, <i>I. Younis, MBBCh, MRCS (Eng), MSc, FRCS (Plast), London, UK</i> | 54 |

Adhesion Barrier

| | |
|---|----|
| Adherent scar after extravasation of cytotoxic drugs, <i>Keck et al. 2008, Handchir Mikrochir Plast Chir; ©Thieme</i> | 56 |
| Treatment of adherent foot tendon, <i>U. Graf, MD, Zurich, Switzerland</i> | 58 |
| Adherent scar at knee, <i>W. Meyer, MD, Fort Malakoff Clinic, Mainz, Germany</i> | 60 |
| Exposed tendon of the hand, <i>J. Federbusch, MD, Rio Grande do Sul, Brazil</i> | 62 |

Donor Sites

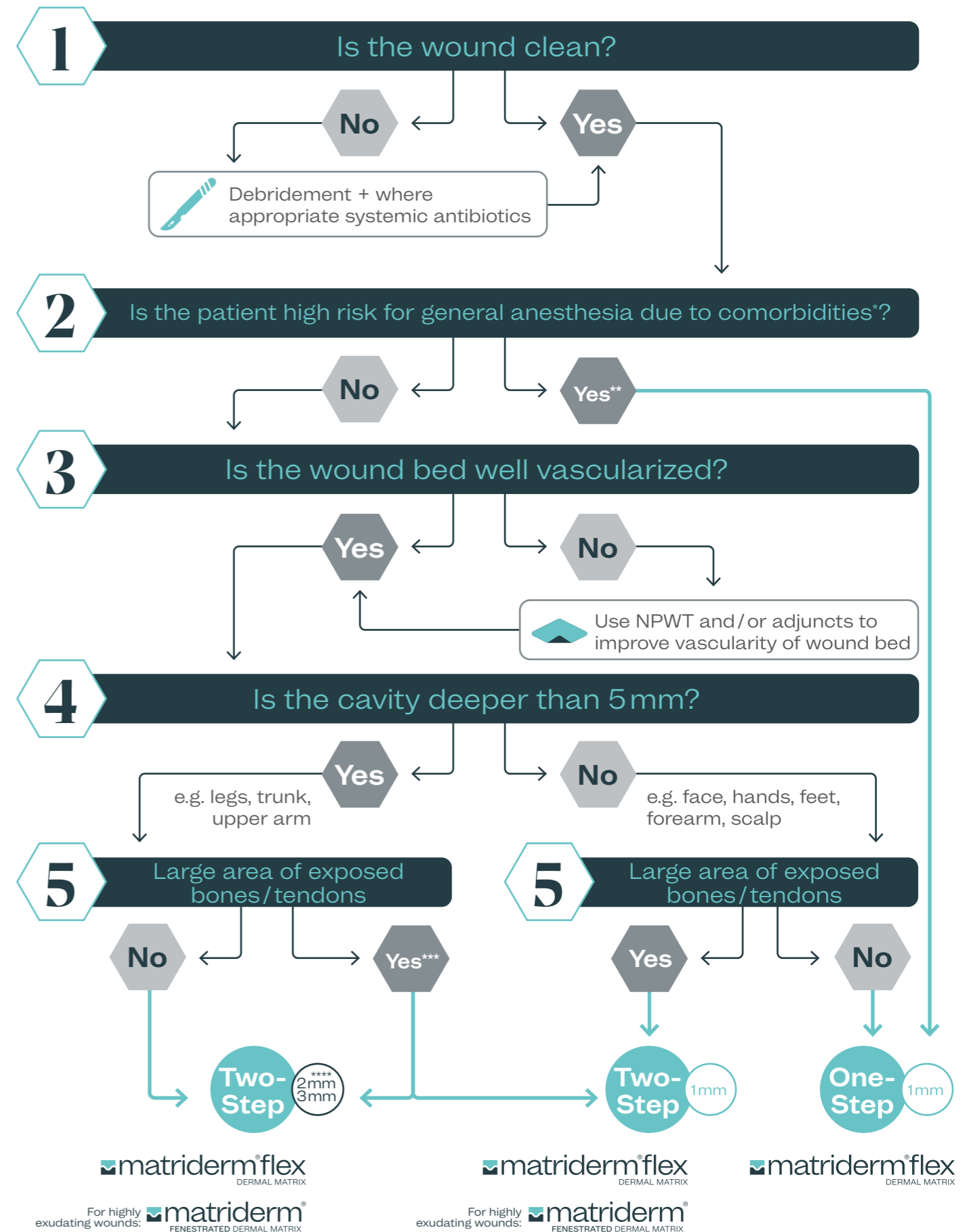
| | |
|--|----|
| Donor Site after Phalloplasty with the Radial Forearm Flap, <i>W. Watfa, MD, Lausanne, Switzerland</i> | 64 |
|--|----|

Preparation of wound bed and application of MatriDerm®

- MatriDerm® is a unique collagen elastin matrix, which serves as a dermal replacement scaffold.
- Dry application of MatriDerm® is recommended. If more than one sheet of MatriDerm® is used, the sheets should overlap by approximately 2–3mm.
- Note that there is no need to fenestrate the lyophilized sheet of MatriDerm®.
- Rehydrate MatriDerm® in the wound bed using saline or Ringer's solution. Please ensure the solution is not warmer than room temperature. Make sure MatriDerm® evenly adheres to the wound bed. Gently remove air bubbles.
- Bolster for compression and splintage to minimize movement between wound bed and MatriDerm®.
- Remove top layer of granulation tissue because it may cause scar tissue.
- Negative Pressure Therapy (NPWT) may be used to optimize the wound bed by stimulating granulation tissue formation, blood vessel sprouting (vascularization) and cell proliferation (e.g. to reduce the area of exposed structures like tendons or bones).¹

Note: upon the discretion of the surgeon and his/her experience with dermal substitutes the procedure and thickness of MatriDerm® can differ from the recommended pathway of the decision tree.

Decision Tree



¹ Panayi A. et al. Evidence based review of negative pressure wound therapy, World J Dermatol. Feb 2, 2017; 6(1): 1-16

* This applies for both local and general anesthesia
 ** Irrespective of depth of cavity and degree of exposes bones/tendons
 *** Depending on surgeon's experience and patient factors
 **** Please ensure that the patient and wound condition are appropriate

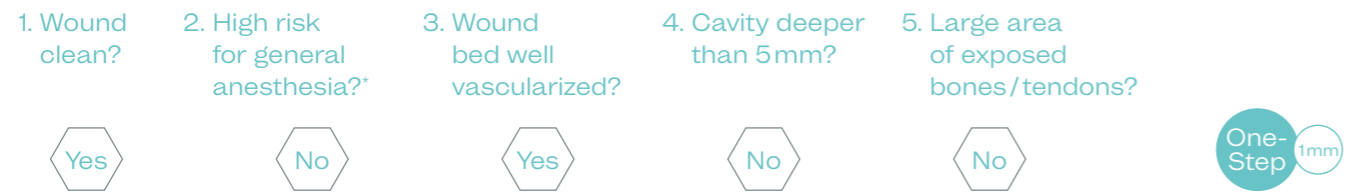
Hand scar revision after burn

Type of Wound Contractile scar revision after burn injury*

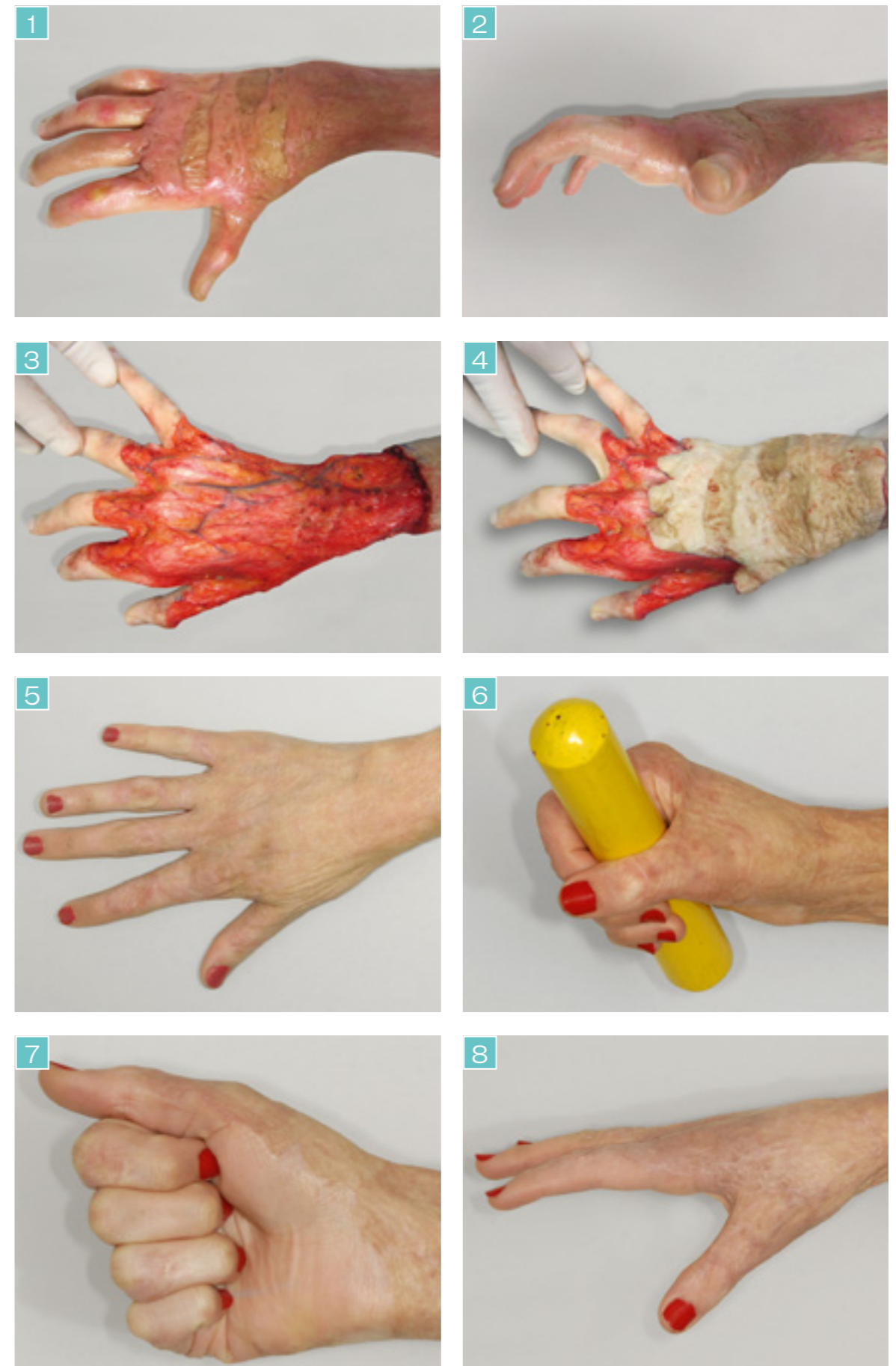Etiology Hypertrophic and contractile scar after 3rd degree flame burn of the right hand. Pronounced hyperextension of the metacarpophalangeal (MCP) joint and complete stiffness of the wrist.

Patient Young female

Decision Tree



Pre-operative: Hyperextension of the MCP joint – function is considerably limited (Fig.1). Fist closure is not possible (Fig.2). Intra-operative: Complete excision of the scar tissue (Fig.3). Intra-operative: The scar tissue – laid back onto the wound bed for the photo – reveals the dimension of the scar contraction, the skin deficit and the substantial functional limitation (Fig.4). Long-term follow-up: Normal function of the hand without any limitations (Fig.5–7).



* Courtesy of L. Kamolz, MD, Graz, Austria

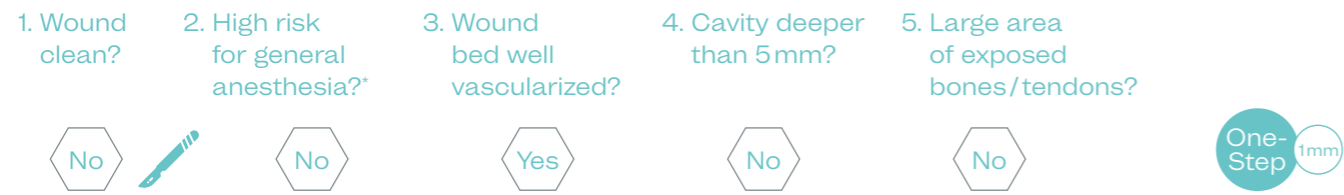
Pediatric scald burn

Type of Wound Scald burn on the foot*

Etiology Burn wound

Patient 2-year-old child

Decision Tree

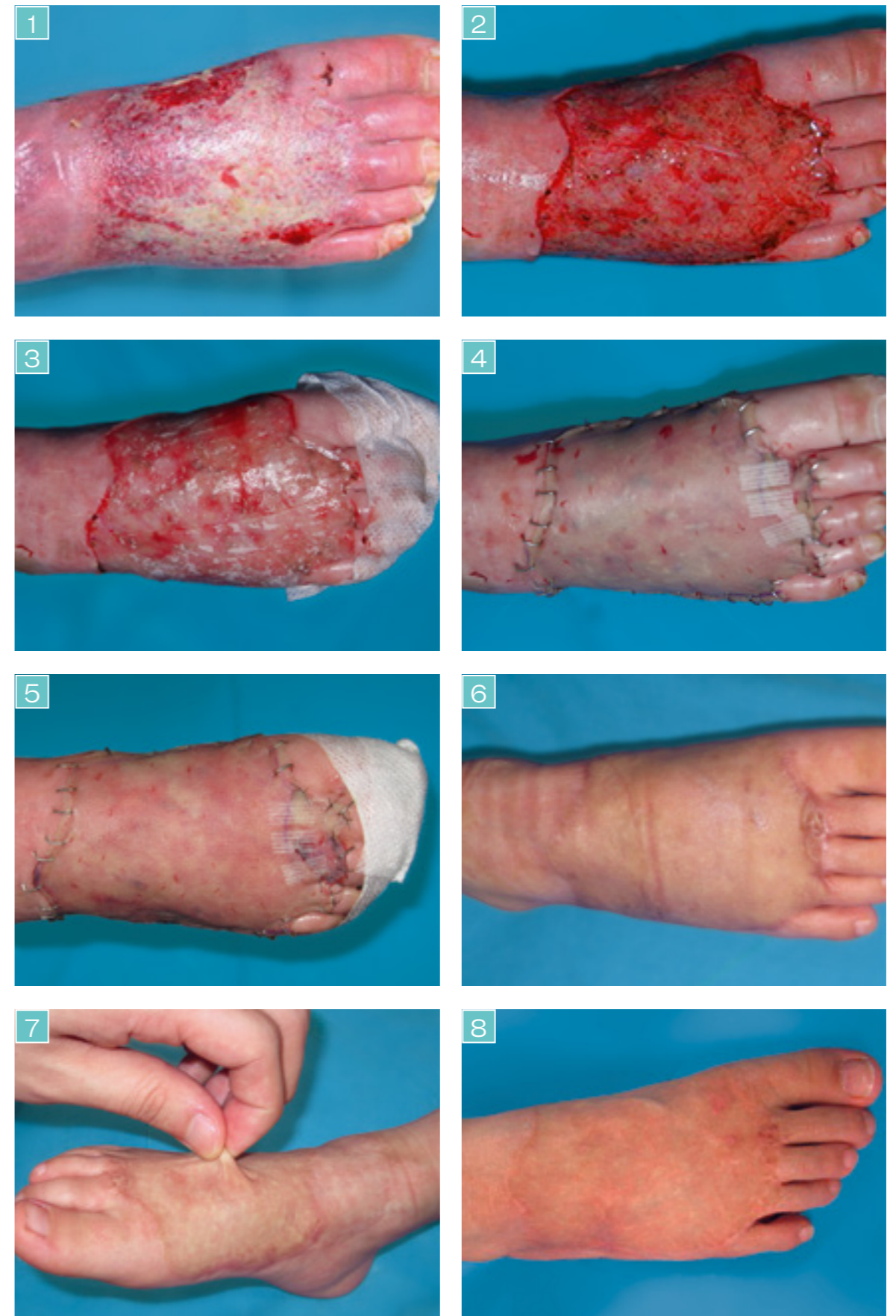

A 2-year-old child presented with a scald burn on the right foot (Fig.1). At the subsequent surgery the wound was carefully debrided (Fig.2). Due to the higher risk of contracture because of the young age of the patient, it was decided to use MatriDerm® in an attempt to prevent scar tissue formation and contracture.

MatriDerm® was applied to the wound bed and trimmed appropriately (Fig.3). A split-thickness skin graft (STSG) was placed on top of MatriDerm® in a One-Step Procedure (Fig.4). The STSG was secured using staples.

At 2 days follow-up the wound showed good signs of healing and good take rate of the graft (Fig.5). At 6 months the wound was completely healed without scarring (Fig.6). At 1 year follow-up the skin demonstrated excellent pliability and good aesthetic result (Fig.7). At 4 year follow-up the grafted area showed same skin color as the surrounding skin (Fig.8). The regenerated skin is growing at the same rate as the surrounding tissue.

This case demonstrates that MatriDerm® can be used successfully in pediatric patients with excellent aesthetic and functional outcomes.



* Courtesy of J. Lee, MD, Seoul, S. Korea

Massive scar contracture on flank

Type of Wound Burn scar revision*

Etiology Scar contracture of burn wound on flank

Patient 56-year-old male

Decision Tree

1. Wound clean?
2. High risk for general anesthesia?*

Yes

Yes

One-Step 1mm

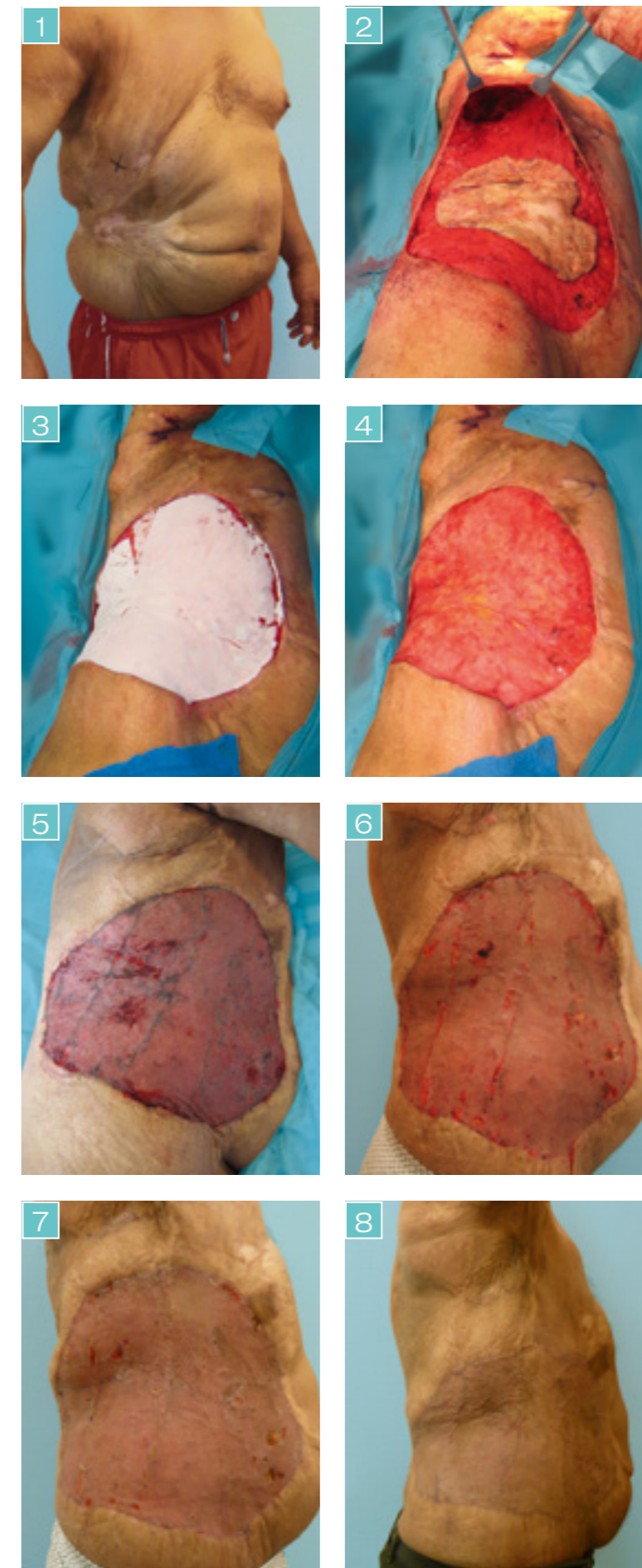
The patient presented with a large scar from a burn wound on the flank 20 years ago (Fig.1). Reason for his request of scar revision was the instability and aesthetic appearance of the scar and skin insensitivity. Comorbidities included a history of peripheral artery occlusive disease and arterial hypertonia.

The scar plate was excised completely and the contractures were released (Fig.2). The resulting defect was covered with multiple dry sheets of MatriDerm® (Fig.3), which were rehydrated in situ (Fig.4).

A split-thickness skin graft (STSG) was positioned over MatriDerm® in a One-Step Procedure. Negative Pressure Wound Therapy (NPWT) was initiated to fixate the graft. After 5 days, the first dressing change was performed and NPWT was discontinued. The wound showed a good take rate of the STSG, with just minimal dehiscence (Fig.5).

Three weeks post-operatively, the graft was almost completely healed, demonstrating markedly reduced tension (Fig.6). One month p.o., the wound was 90% tension free, with just a few small wounds (Fig.7).

Six months p.o., there was no loss of functionality, with just a small scar cord in the axilla, that does not trouble the patient. Despite the still lowered mamilla, the patient is satisfied with the current result (Fig.8).



* Courtesy of J. Grünert, MD, St. Gallen, Switzerland

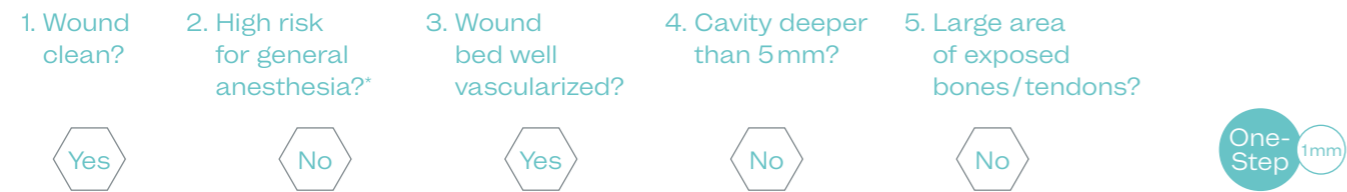
Revision surgery of burn scar at the lower limb

Type of Wound Burn sequela - unstable scar and functional impairment due to contractures*

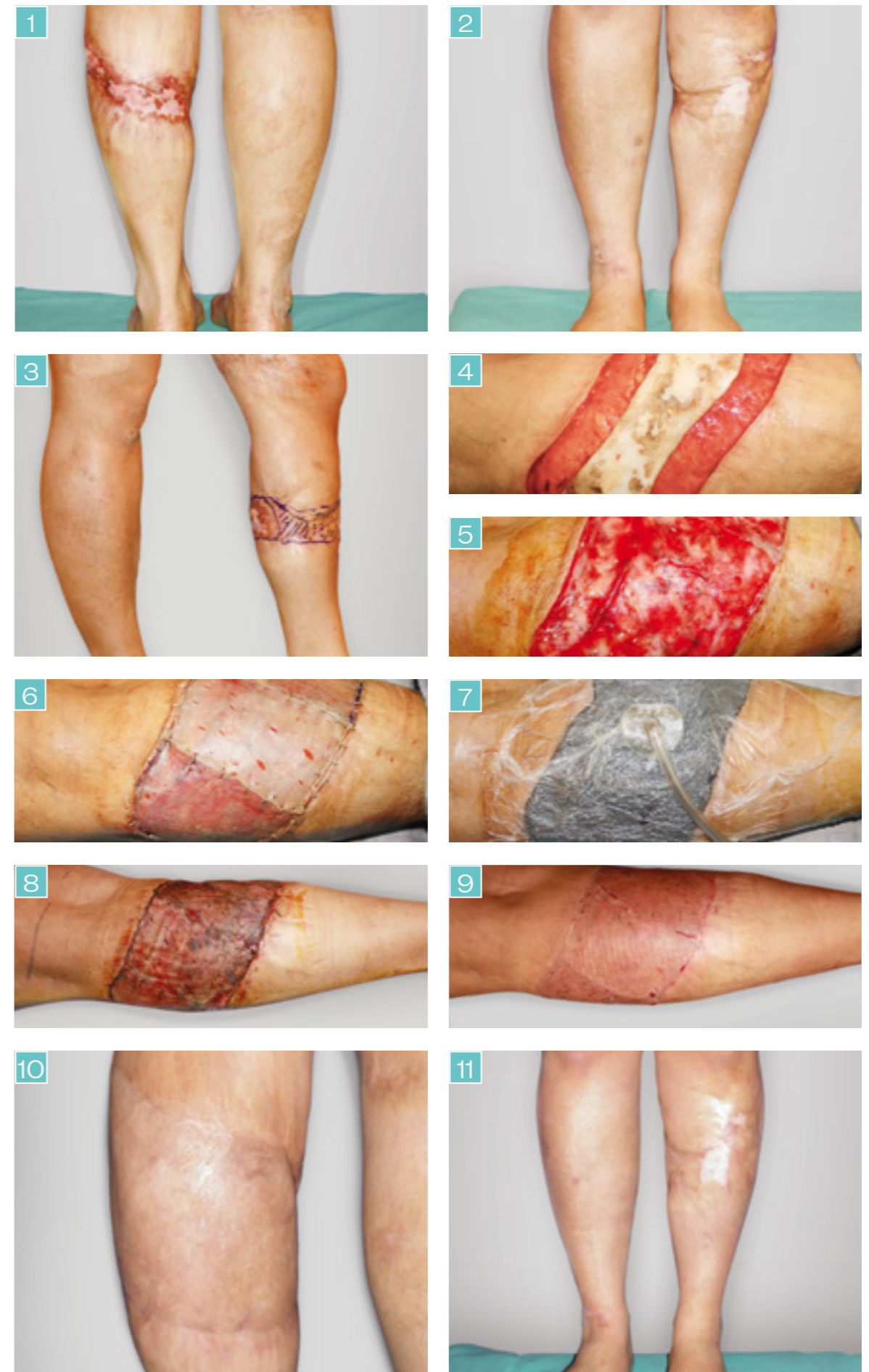Etiology Flame burn in childhood (at age 8)

Patient 27-year-old female

Decision Tree



Aspect of the wound before operation (Fig.1,2). Pre-operative marking of the area to be excised (Fig.3). Aspect of the wound after scar resection with release of healthy tissue. In order to show the extend of contracture release the scar tissue was put back onto the wound bed for this photo (Fig.4). Application of MatriDerm® (Fig.5), covered with fenestrated split-thickness skin graft (Fig.6). Negative pressure wound therapy as dressing (Fig.7). Result after 2 weeks (Fig.8). Result after 3 months (Fig.9). Result 1 year later (Fig.10,11). Pleasing functional and aesthetic outcome with full pain release. Complete and stable healing of the wound.



* Courtesy of A. Modarressi, MD, Geneva, Switzerland

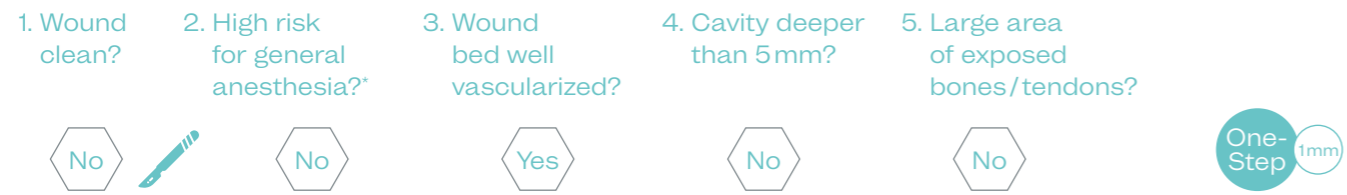
Flame burn on chest and neck

Type of Wound Flame burn on chest and neck*

Etiology Burn wound

Patient 42-year-old male

Decision Tree

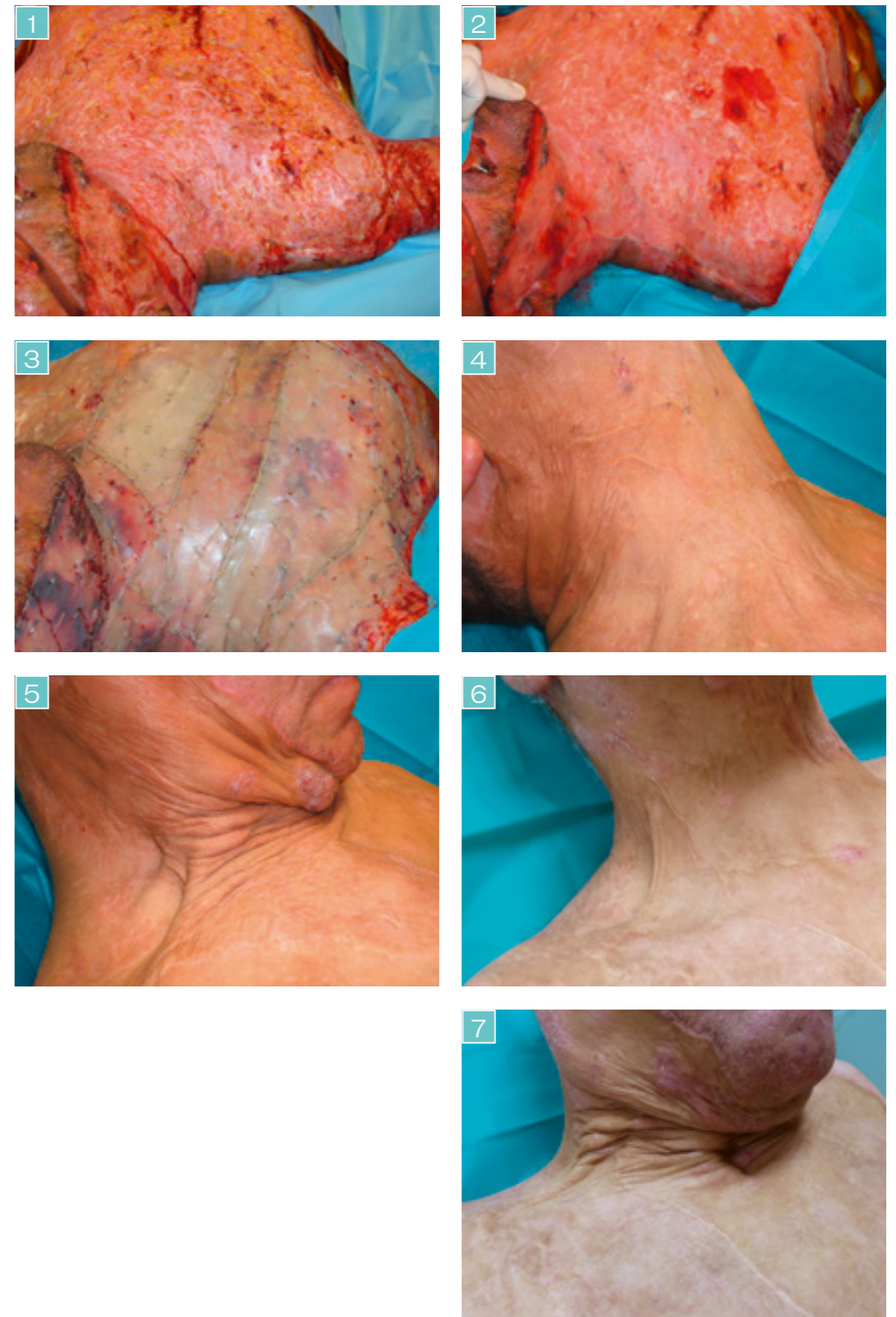


A 42-year old male presented with a flame burn on chest and neck (60% TBSA) (Fig.1). This is a challenging region due to high incidents of contractions, so high elasticity is very important.

The wound was carefully debrided to ensure a vital wound bed. MatriDerm® (1mm) was applied to the wound bed (Fig.2).

A split-thickness skin graft (STSG) was placed on top of MatriDerm® in a One-Step Procedure (Fig.3).

Two and five years post-operatively, the grafted area showed very good elasticity and skin colour. The good functional outcome was demonstrated by the unlimited extension of the neck (Fig.4-7). This case demonstrates that MatriDerm® can be used successfully in demanding region like the neck with excellent aesthetic and functional outcome.



* Courtesy of E. Dantzer, MD, Toulon, France

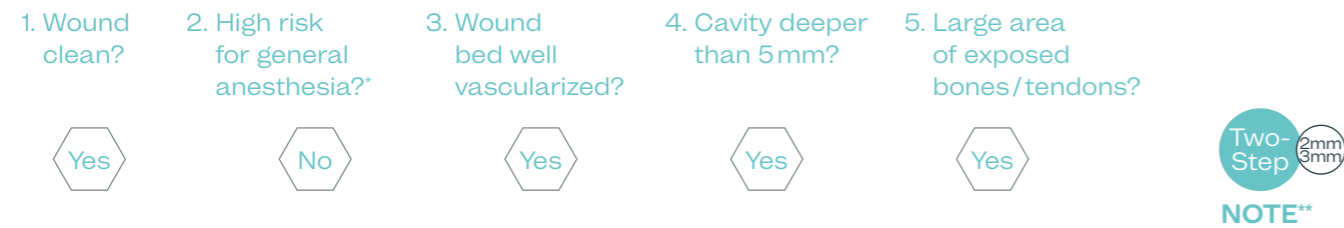
Degloving of the forearm in a work accident

Type of Wound Avulsion injury*

Etiology Avulsion with degloving of the upper extremity with release of compartments

Patient 20-year-old male

Decision Tree

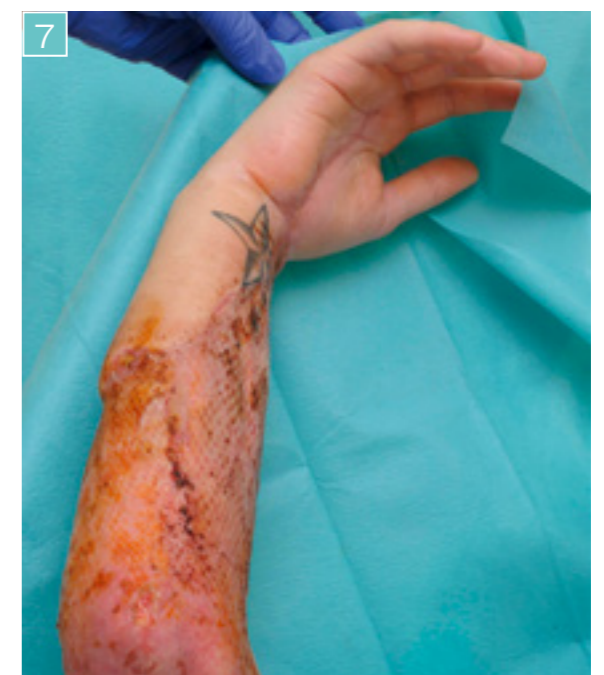
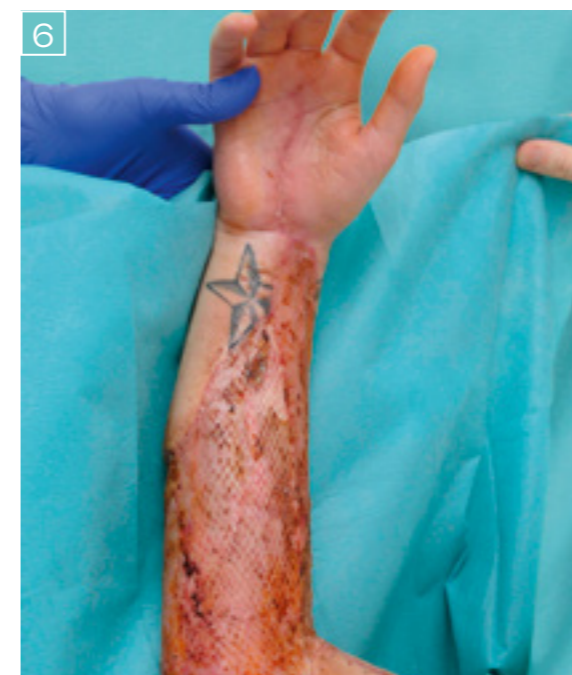
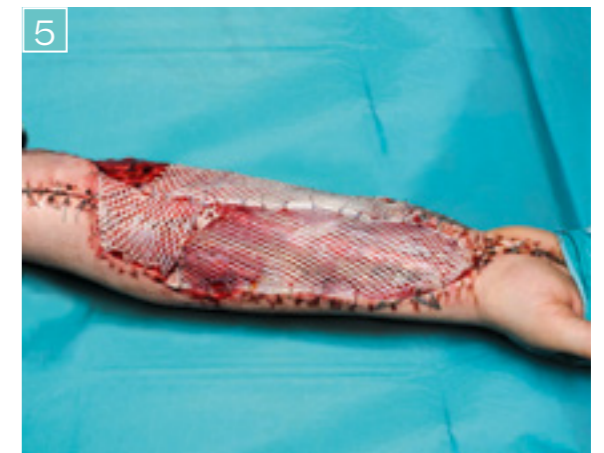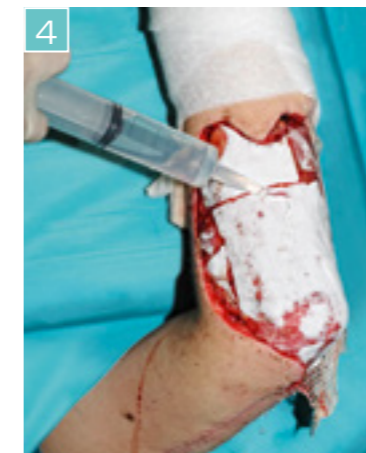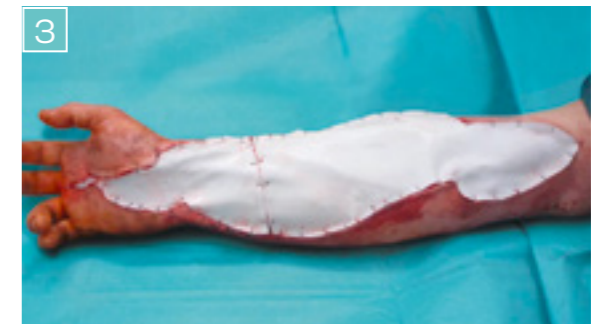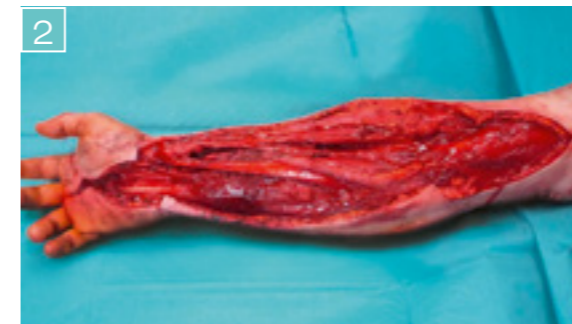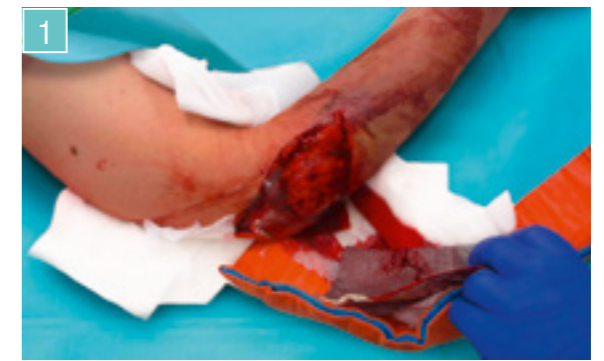The patient suffered from a work accident where his arm was crushed into an industrial roller, which resulted in multiple bone fractures and degloving of his right arm (Fig. 1).

Two days after the accident a fasciotomy was performed to release the compartment syndrome of the forearm and hand (Fig. 2). The defect was covered with Epigard to clean and condition the wound bed (Fig. 3).

Twelve days after the accident the debrided wound was covered with dry sheets of MatriDerm®, which were cut into shape to fit within the wound bed. MatriDerm® was rehydrated with sterile physiological saline (Fig. 4), immediately followed by placement of a meshed split-thickness skin graft on top of MatriDerm® in a One-Step Procedure (Fig. 5). Negative pressure wound therapy was initiated post-surgery.

At the follow-up visit three weeks later, stable wound closure with complete integration of the skin graft was observed (Fig. 6, 7). The patient had good initial mobility of his elbow and wrist. Five months later the patient was back at work.



* Courtesy of M. Kerl, MD, Graz, Austria

Epigard by Biovision GmbH

** The surgeon used MatriDerm® in a One-Step procedure. Upon the discretion of the surgeon and his/her experience with dermal substitutes the procedure and thickness of MatriDerm® can differ from the recommended pathway of the decision tree.

Degloving injury at lower leg

Type of Wound Significant soft tissue loss of the left lower leg and foot with visible tendons and periosteal structures of the medial ankle*

Etiology Degloving injury

Patient 71-year-old male

Decision Tree

1. Wound clean?
2. High risk for general anesthesia?*

No



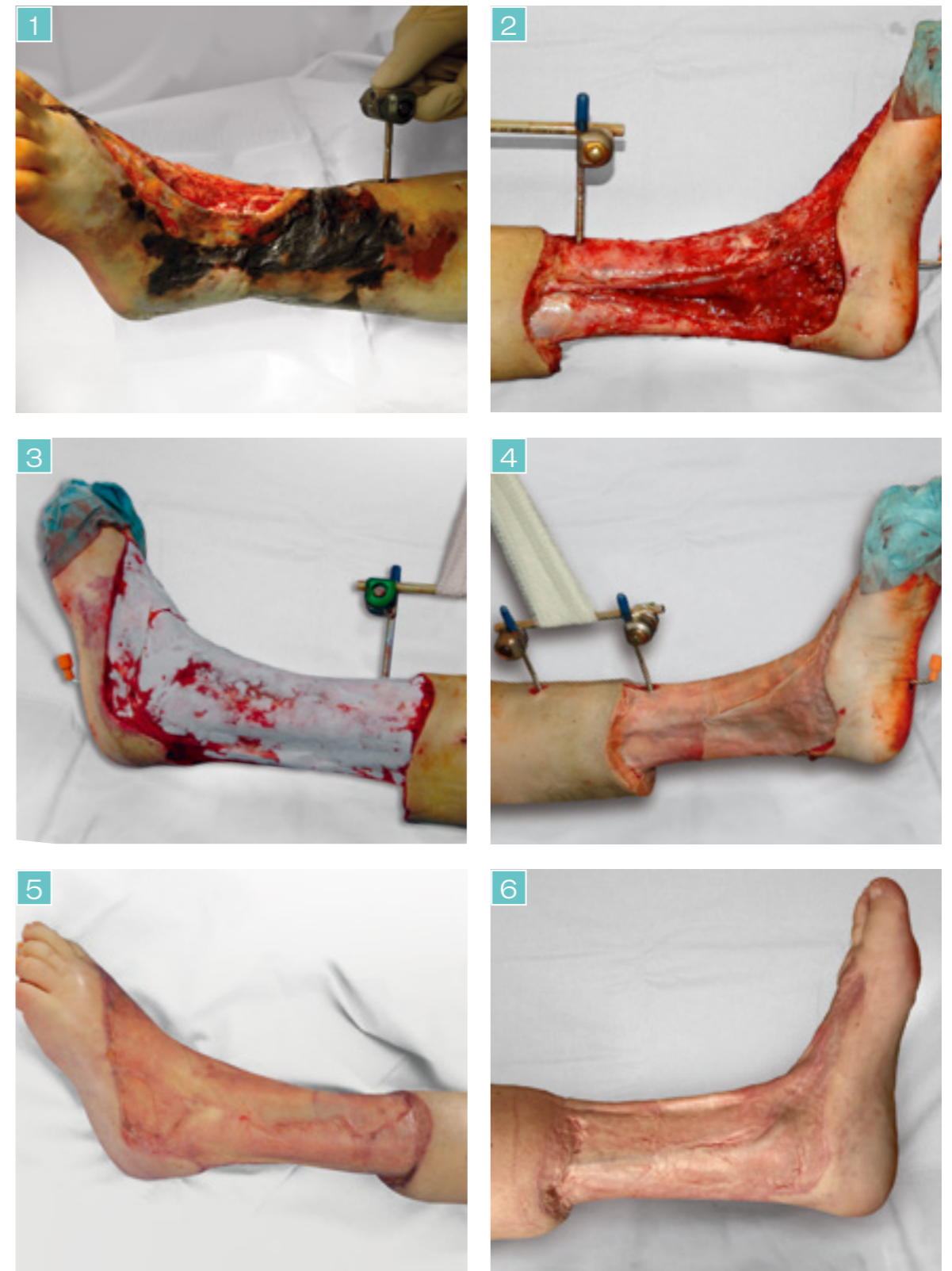
Yes

One-Step 1mm

This 71-year-old patient suffered a degloving injury of the left lower leg and foot (Fig.1). After operative debridement, there was significant soft tissue loss with visible tendon and periosteal structures of the medial ankle (Fig.2). Angiography showed that the lower leg and foot were only being nourished by an arteriosclerotic tibialis posterior artery.

Defect coverage was performed using 1mm MatriDerm® (Fig.3) in a One-Step Procedure with unmeshed split skin grafts in combination with one week of negative pressure wound therapy to fix the grafts (Fig.4).

With this procedure the leg could be saved and showed a stable wound closure - one month p. o. (Fig.5). Two years after the accident the patient was able to wear normal shoes and clinical gait analysis demonstrated a perfect functional outcome (Fig.6). The patient refused to have any further procedure done to improve the aesthetic outcome.



* Courtesy of M. Öhlbauer, MD, Murnau, Germany

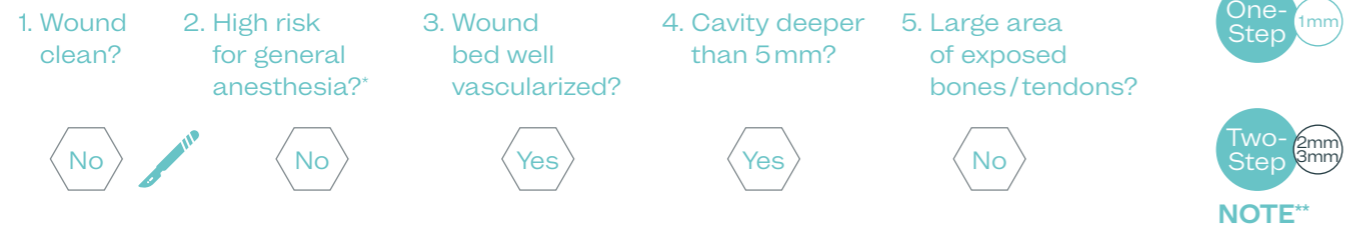
Crush trauma by a school bus

Type of Wound Deep soft tissue defect with involvement of the fascia, right lower leg*

Etiology Crush trauma by a school bus

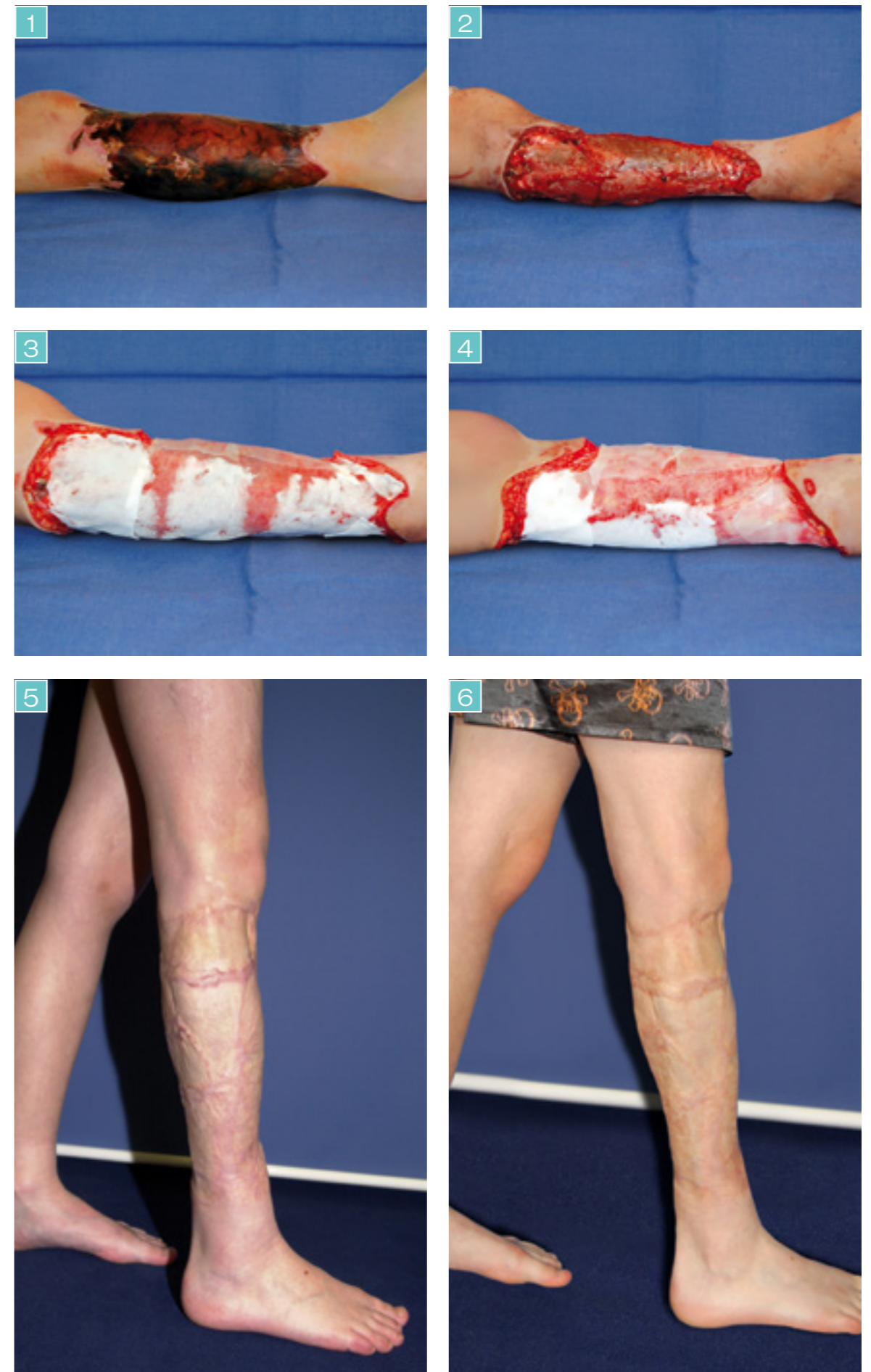
Patient 7-year-old boy

Decision Tree



The patient was transferred to a special trauma clinic on day 5 post injury. Two-thirds of the proximal lower leg showed necrotic tissue (Fig.1). Parts of the lower leg fascia were destroyed. After debridement vital paratenon at the tibia was exposed (Fig.2). The tissue defect was covered with 1mm MatriDerm® and unmeshed split-thickness skin graft in a One-Step Procedure (Fig.3,4). Fixation was performed by negative pressure wound therapy for 1 week.

Thereafter conventional dressing (fatty gauze/bulky gauze/tight bandaging) was performed and the wound healed quickly without any complications. Aftercare with compression garments. Good functional and aesthetic result was achieved. Fig.5:18 months after injury. The transplanted skin was pliable and soft so that the patient was able to return to normal life. 7 years after the surgery the aesthetic outcome has further improved (Fig.6). No scar contracture release surgeries have ever been necessary because the new skin has grown naturally along with the boy's legs.



* Courtesy of M. Öhlbauer, B. Wallner and M. Miltz, MD, Murnau, Germany

** The surgeon used MatriDerm® in a One-Step procedure. Upon the discretion of the surgeon and his/her experience with dermal substitutes the procedure and thickness of MatriDerm® can differ from the recommended pathway of the decision tree.

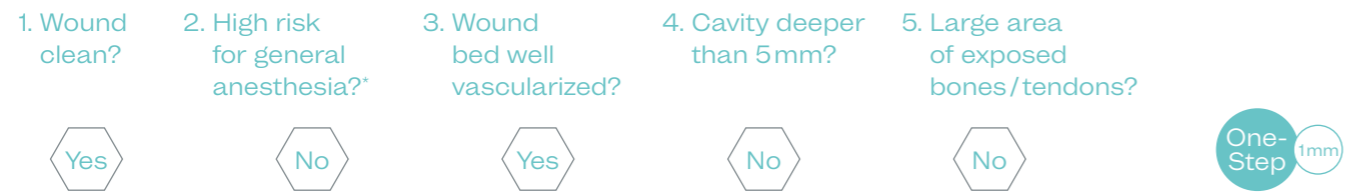
Avulsion injury at the foot with exposed Achilles tendon

Type of Wound Soft tissue defect at the heel with exposed Achilles tendon*

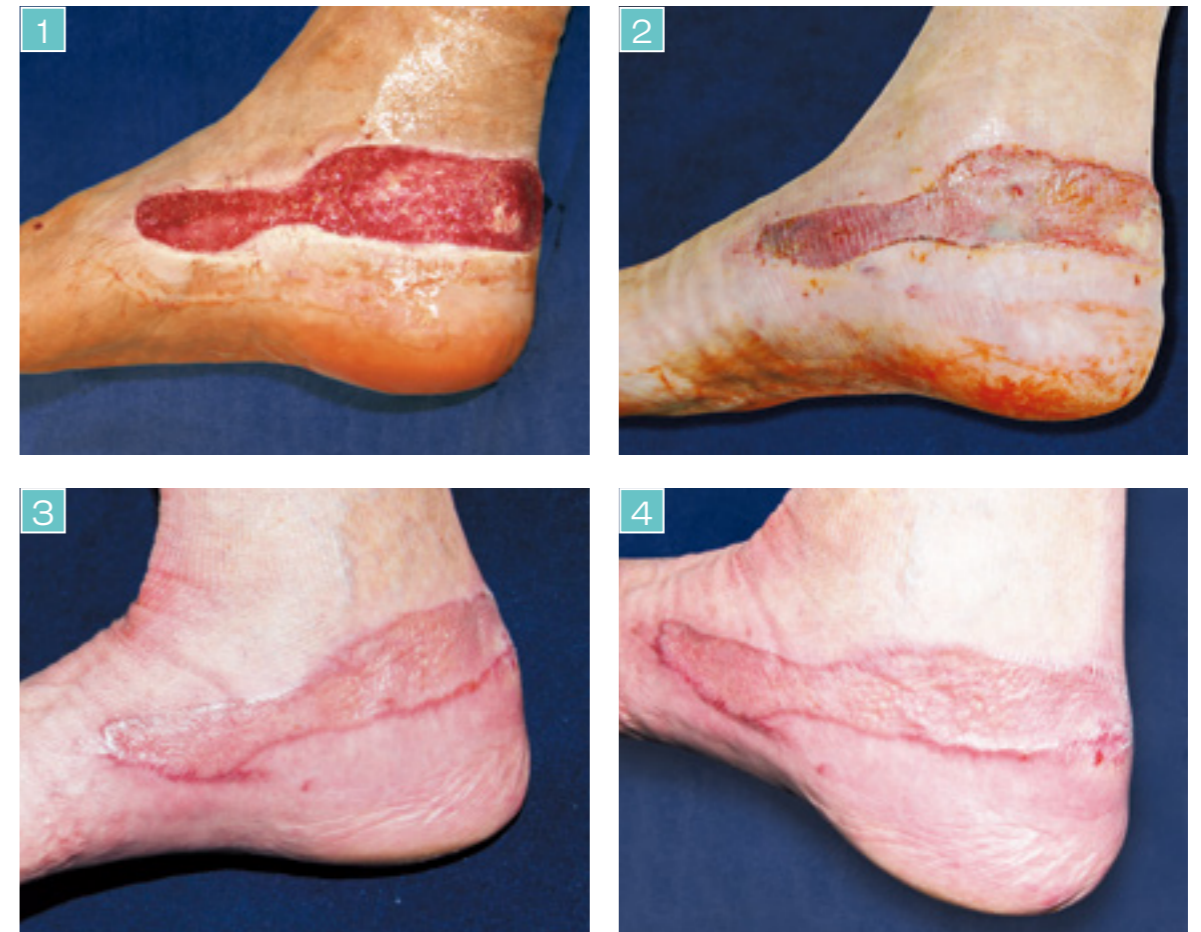
Etiology Avulsion at the right foot after motor-bike injury

Patient 60-year-old patient

Decision Tree



In this case a 60-year-old patient was hospitalized with an acute avulsion after motor-bike injury. The intra-operative view revealed a defect at the heel and a 2cm exposed Achilles tendon (Fig.1). The wound was treated with 1mm MatriDerm® and unmeshed split-thickness skin graft in a One-Step Procedure. 2.5 weeks later the wound area showed a closed skin with good tendency to heal (Fig.2). The physiotherapy started at this stage. A follow up of 5 weeks p. o. demonstrated a good development with a completely stable wound also over the Achilles tendon (Fig.3,4).



* Courtesy of U. Graf, MD, Zurich, Switzerland

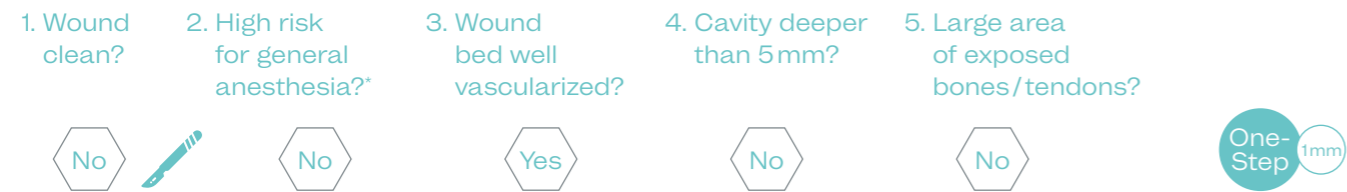
Infected dog bite at the dorsum of the hand

Type of Wound Infected, necrotic full-thickness wound*

Etiology Dog bite

Patient 64-year-old female

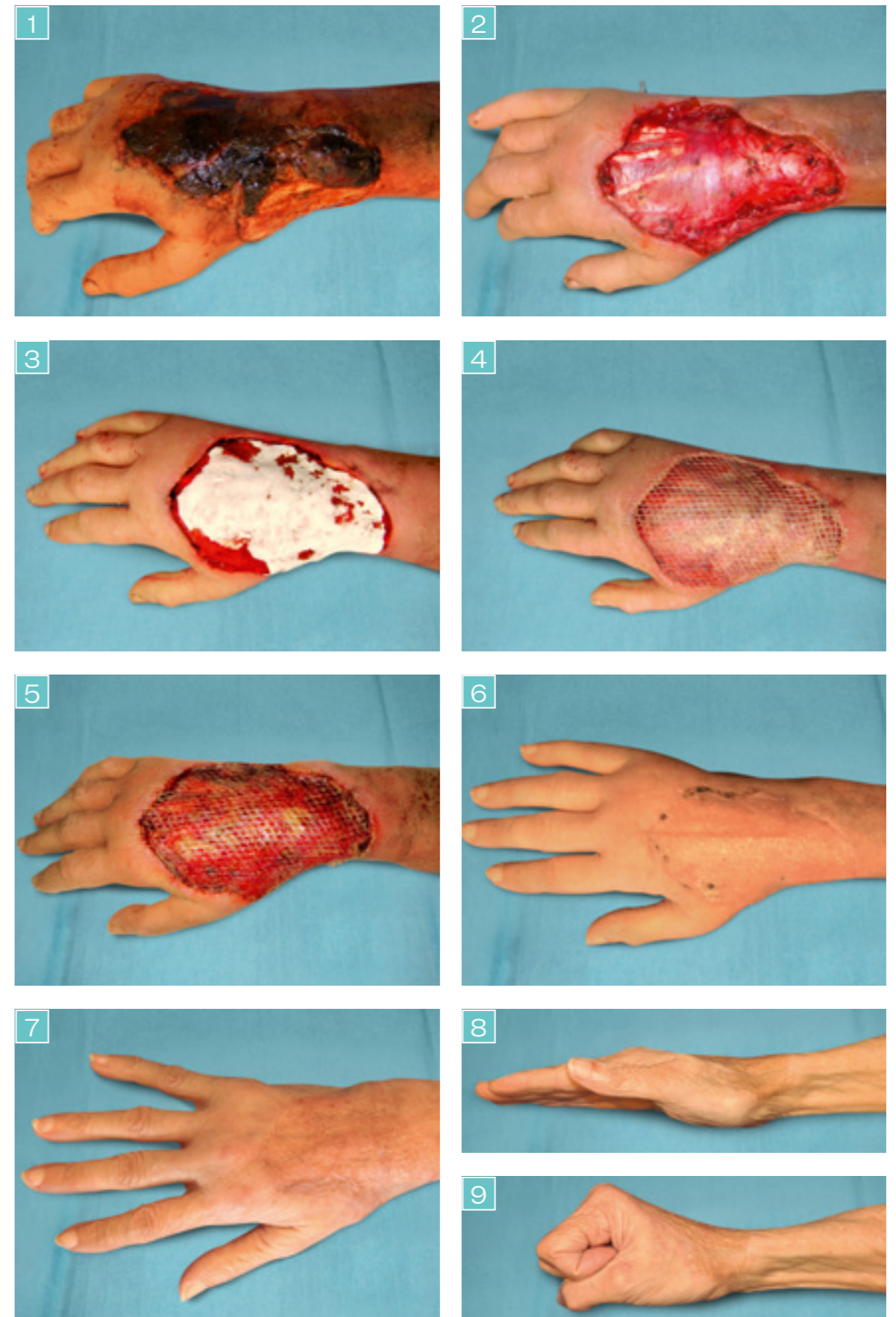
Decision Tree



After one month of pre-treatment of a dog bite in a general hospital (three sessions of debridement, splinting of the fascia and negative pressure wound therapy) the patient was transferred to a specialized clinic with plastic and reconstructive surgery. Pre-operative view, 4 weeks after injury: Wound bed was still necrotic (Fig.1). Day 0: Wide and deep excision of the wound to avoid further complications (Fig.2). After preparation of an adequate wound bed, dry 1mm MatriDerm® was applied to the wound (Fig.3).

After rehydration of MatriDerm® a meshed split-thickness skin graft was applied in a One-Step Procedure (Fig.4). Fixation was performed by sutures. The wound dressing consisted of fatty gauze, bulky dressing and tight bandaging. Day 6 p. o.: First dressing change with a stable wound and excellent take of the autograft (Fig.5). 3 months p. o.: Stable wound closure of the hand (Fig.6). 2 years follow-up: The long-term result demonstrated full range of motion of the hand and a good aesthetic outcome (Fig.7-9).

Trauma



* Courtesy of U. Hug, MD, Luzern, Switzerland

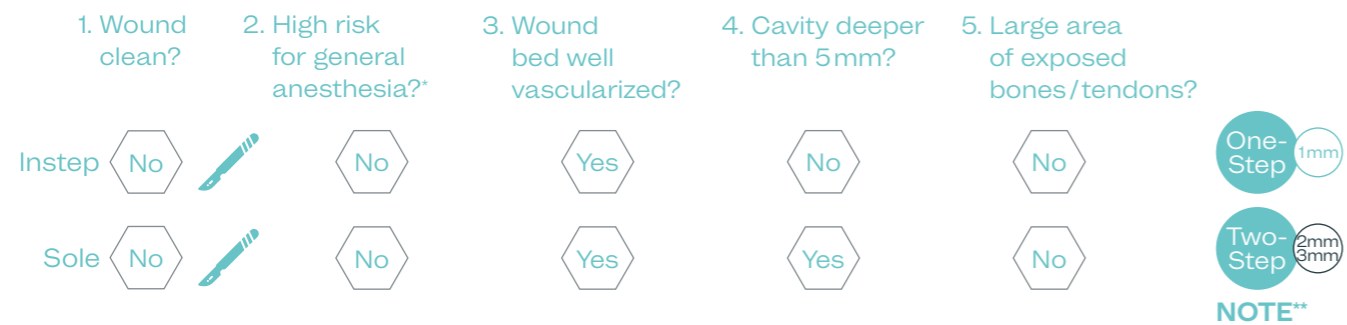
Deglovement instep and plantar regions after motor-bike injury

Type of Wound Deep soft tissue defect on the instep and plantar regions*

Etiology Motor-bike injury with deglovement

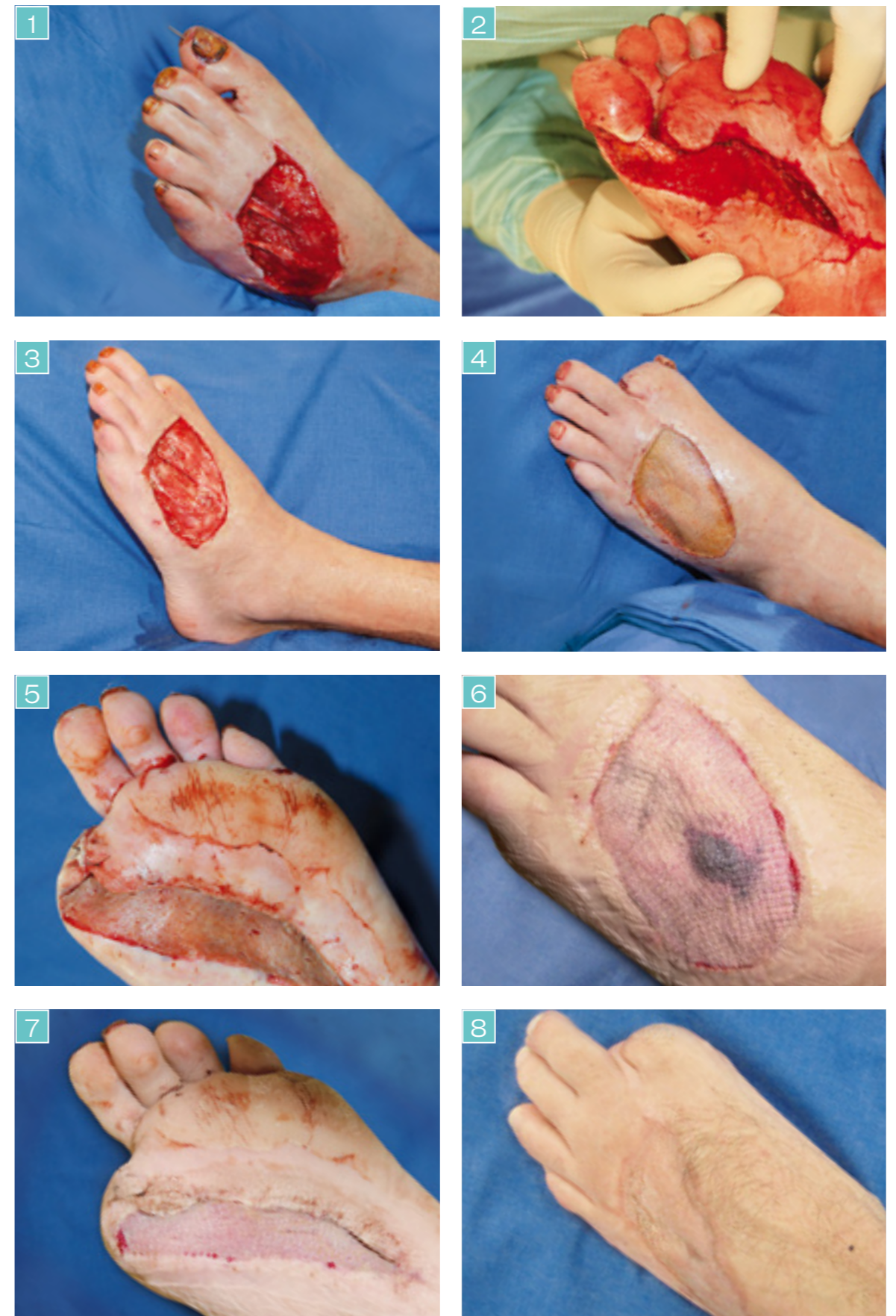Patient 45-year-old male

Decision Tree



One week after motor-bike injury the traffic victim was transferred to a specialized trauma hospital with deep soft tissue loss on the instep and sole of the foot (Fig.1, 2). Debridement was performed including amputation of the necrotic first toe (Fig.3). Wound closure was achieved by using 1mm MatriDerm® in combination with unmeshed split-thickness skin graft in a One-Step Procedure (Fig.4,5).

Fixation was performed with vacuum therapy for 1 week. Excellent take rate at the first dressing change (Fig.6,7). A small hematoma under the graft was associated with the vacuum base and can be avoided by bringing the vacuum base outside the wound area. However, this did not compromise the take. Follow-up 3 months later showed a completely healed foot with excellent elasticity of the new skin (Fig.8).



* Courtesy of M. Öhlbauer, B. Wallner and M. Miltz, MD, Murnau, Germany

** The surgeon used MatriDerm® in a One-Step procedure. Upon the discretion of the surgeon and his/her experience with dermal substitutes the procedure and thickness of MatriDerm® can differ from the recommended pathway of the decision tree. Furthermore the surgeon performed two MatriDerm® procedures at the same time and therefore decided for a One-Step procedure for both wounds.

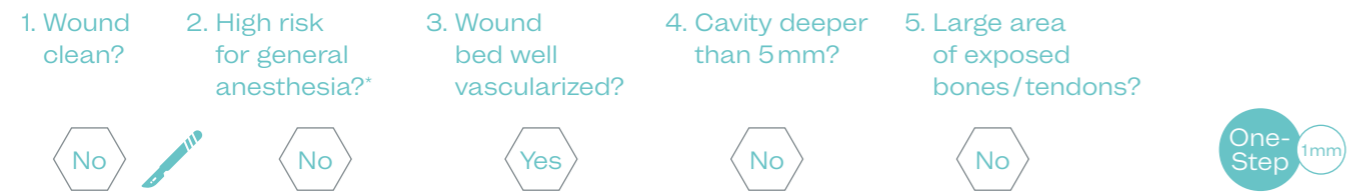
Circular saw injury

Type of Wound Severe soft tissue defect of the left hand*

Etiology Circular saw injury, no co-morbidities

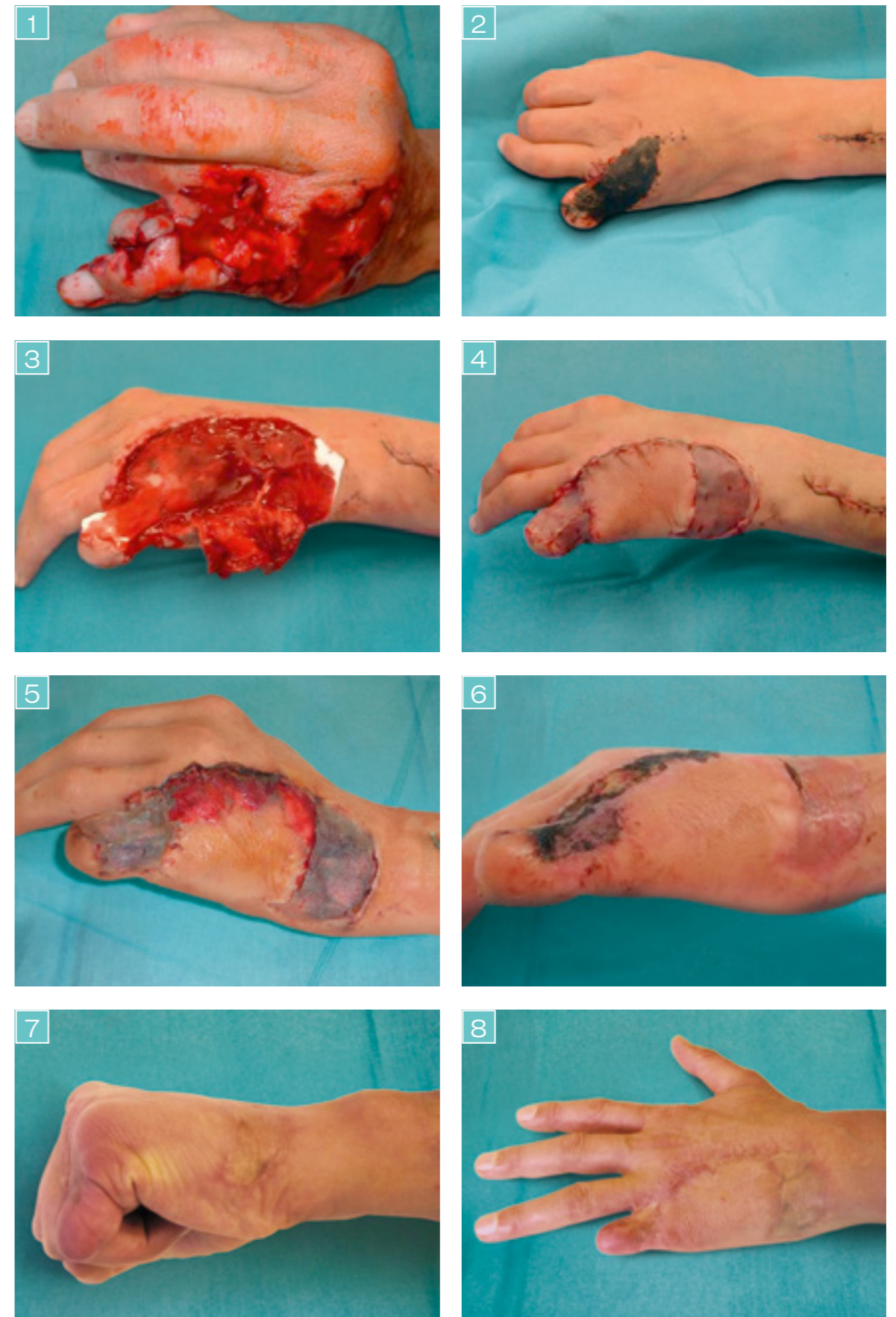
Patient 40-year-old male

Decision Tree



Initial view of the circular saw injury at the hand showing a deep soft tissue defect with involvement of the auricular and the annular finger (Fig.1). Based on the bone status a partial amputation to the mid-joint of the auricular finger was necessary. The wound closure was done with a retrograde pedicular forearm flap. Three days later the flap suffered from a necrosis caused by a septal vascular anomaly (Fig.2). 13 days after injury: Second surgery was required due to the flap loss.

Day 0: Preparation and coverage of the wound with a new local flap complemented by 1mm MatriDerm® in combination with unmeshed split-thickness skin graft in a One-Step Procedure (Fig.3,4). 5 days p. o.: First dressing change showing a little wound edge necrosis of the local flap and good take of the split-skin transplant with vital coloration (Fig.5). 4 weeks p. o.: Secondary healing of the flap and stable wound closure (Fig.6). 6 months p. o.: Good wound closure with normal skin elasticity and functionality in the reconstructed area (Fig.7, 8).



* Courtesy of L. Mathys, MD, Bern, Switzerland

Trauma by car accident

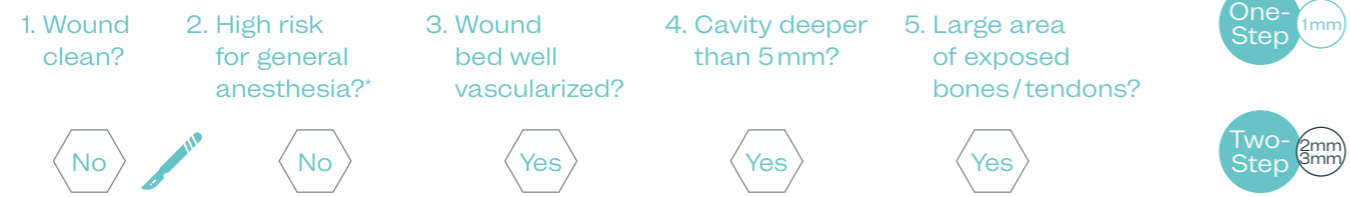
Trauma

Type of Wound Laceration of the left lower leg and foot*

Etiology Trauma by car accident

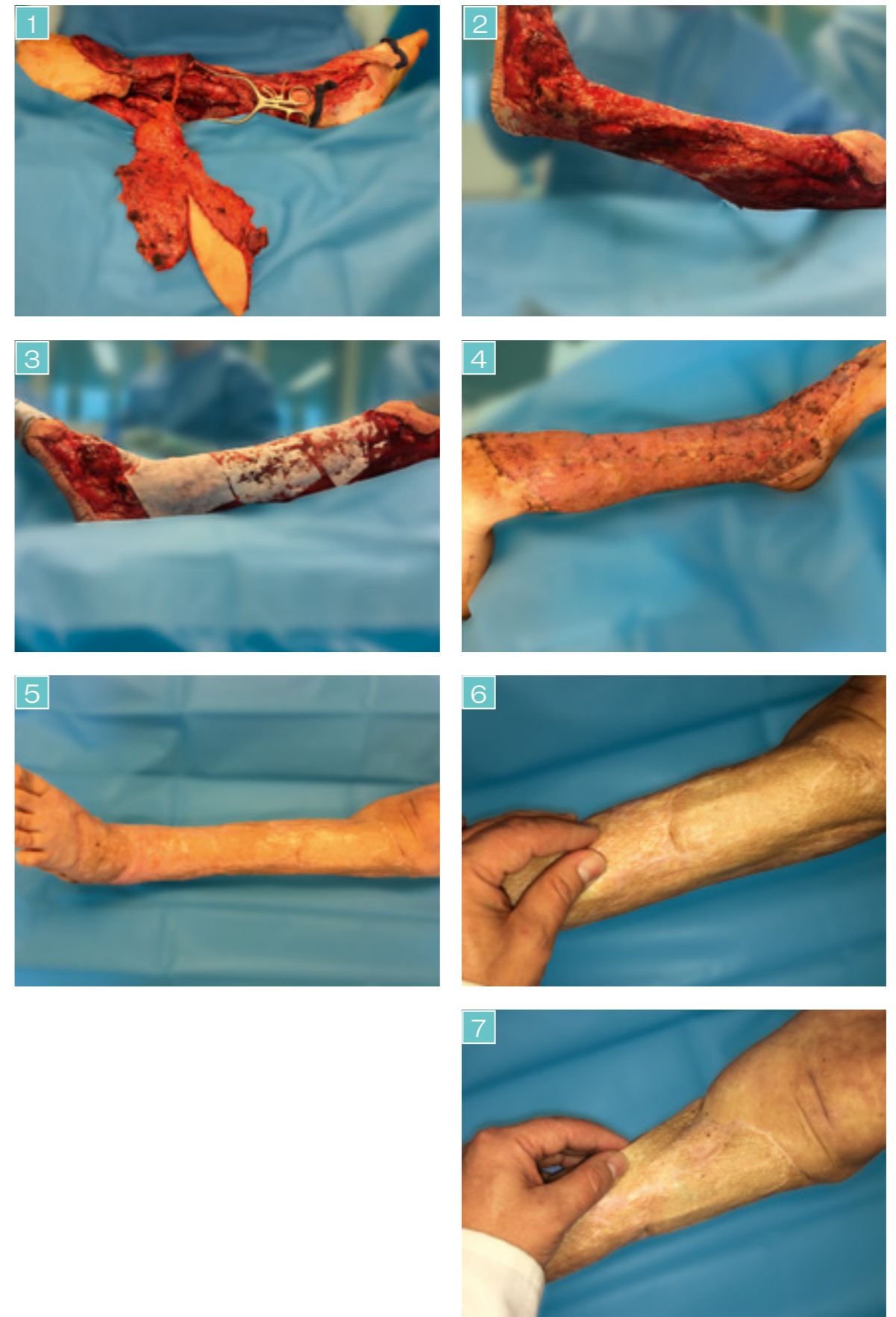
Patient 55-year-old female

Decision Tree



This 55-year-old patient suffered a laceration of the left lower leg and foot (Fig.1). After operative debridement, there was significant soft tissue loss (Fig.2). Defect coverage was performed with a free latissimus dorsi-serratus flap to replace the soft tissue loss. On top of the muscle flap a dry MatriDerm® (1mm) was placed (Fig.3) and rehydrated in situ. A meshed split-skin graft (meshed 1:1.5) was placed on top of the rehydrated MatriDerm® in a One-Step Procedure.

Fixation was performed by Negative Pressure Wound Therapy (NPWT) for 5 days. At the follow-up visit 4 weeks later, stable wound closure with complete integration of the skin graft was observed (Fig.4). Walking training was performed beginning with 14 days p.o.. Good functional and aesthetic (Fig.5) result was achieved. Fig.6 and 7: 24 months after injury. The transplanted skin was pliable and soft. Both, the surgeon and the patient, were satisfied with the functional and aesthetic outcome.



* Courtesy of D. F. Kalbermatten, MD, Basel, Switzerland

** The surgeon used MatriDerm® in a One-Step procedure. Upon the discretion of the surgeon and his/her experience with dermal substitutes the procedure and thickness of MatriDerm® can differ from the recommended pathway of the decision tree.

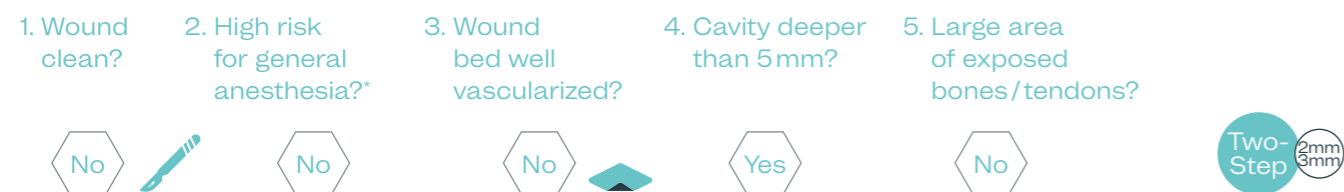Necrotizing Fasciitis of abdominal wall

Type of Wound Extensive loss of abdominal skin, soft tissue and musculature with bowel and slough at the wound base with undermined lateral cavities*

Etiology Post pelvic surgery for gynecological cancer

Patient 55-year-old female

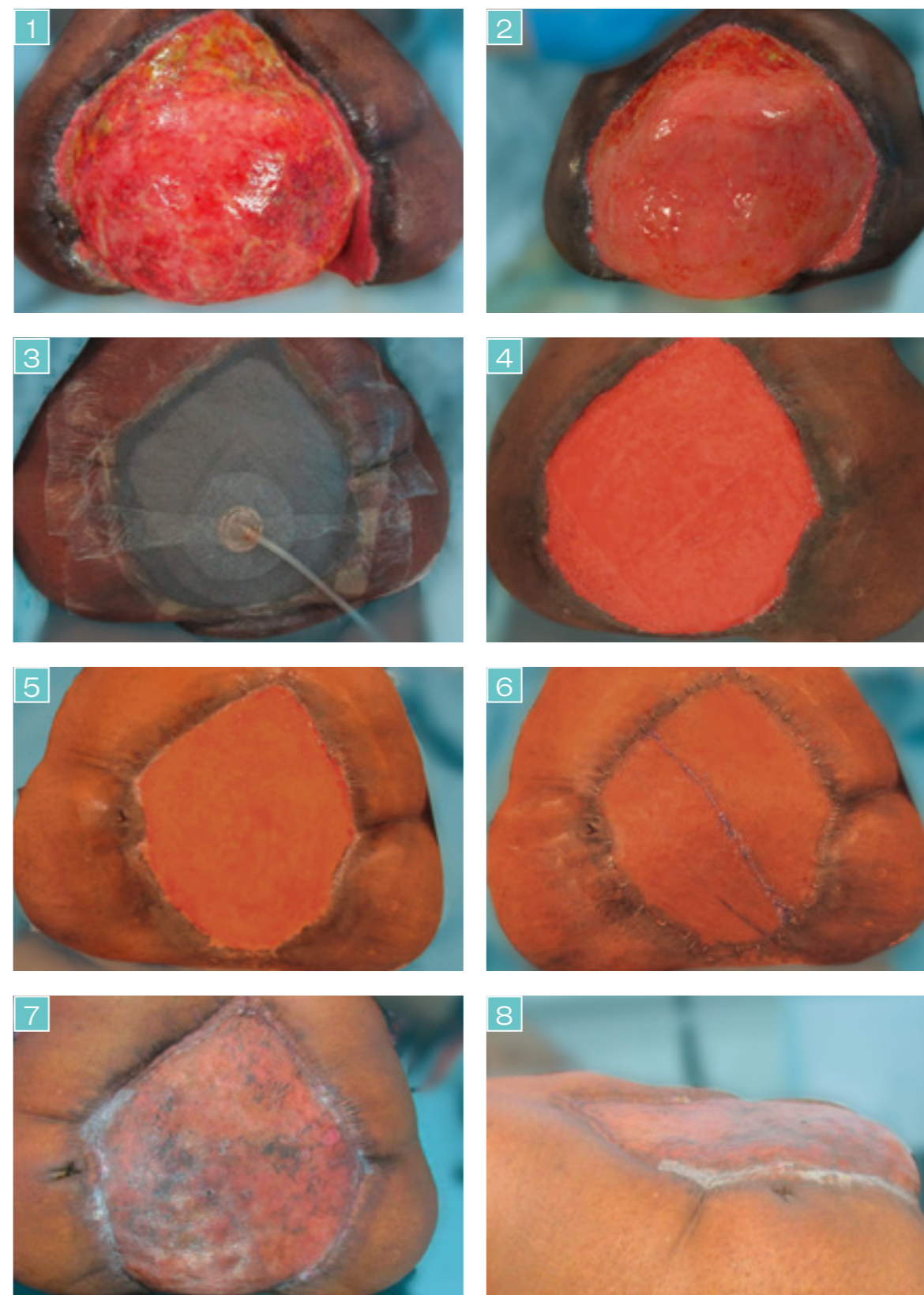
Decision Tree



This patient required extensive life saving abdominal wall debridement after developing necrotizing fasciitis following ovarian cancer surgery. After debridement, she was admitted to the intensive care unit for several weeks with an 'open abdomen' measuring 34x33cm. There was exposed bowel covered by a fragile layer of granulation tissue and yellow slough with discharging cavities under the skin flaps laterally (Fig.1). The rectus muscles had retracted laterally and, therefore, it was inappropriate and unsafe to attempt an abdominal wall reconstruction using mesh and/or advancement techniques at that stage. The objective was to get the wound healed in a timely manner with as much protection and padding over the bowel so the patient could commence the rest of her oncologic treatment that included chemotherapy.

Following NPWT (-75mmHg) for wound preparation, the wound was not only cleaner, with reduced lateral cavities, but also smaller measuring 31x30cm (Fig.2). Coverage of the defect could now be attempted in a Two-Step Procedure with two pieces of 2mm MatriDerm®. These were used to cover the entire wound using standard NPWT foam with a silicone interface to reduce risk of foam integration (Fig.3). After two weeks, the MatriDerm® had completely integrated and formed a scaffold for more granulation tissue with complete obliteration of the lateral cavities and indentations (Fig.4).

Prior to applying the Split-Thickness Skin Graft, the top layer of granulation tissue was removed to get rid of any biofilm and pathogens leaving a fresh bleeding wound bed (Fig.5). The Split-Thickness Skin Graft was harvested from the lateral thigh, fenestrated (not meshed) and bolstered to the wound with NPWT (Fig.6). Six weeks postoperatively, the graft was stable, there were no lateral cavities or indentations and the patient was discharged with better protection and padding over the bowel to enhance her quality of life whilst having adjunctive oncological treatment (Fig.7 & 8).



* Courtesy of I. Younis, MBBCh, MRCS (Eng), MSc, FRCS (Plast), London, UK

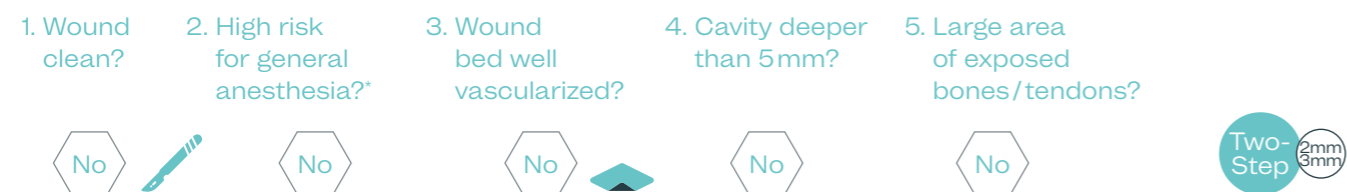
Necrotizing Fasciitis of the lower leg

Type of Wound Almost complete circumferential loss of skin and soft tissue of lower leg with exposed gastrocnemius tendons without vascularity*

Etiology Life and limb saving debridement for necrotizing fasciitis in a type 1 diabetic

Patient 45-year-old male

Decision Tree

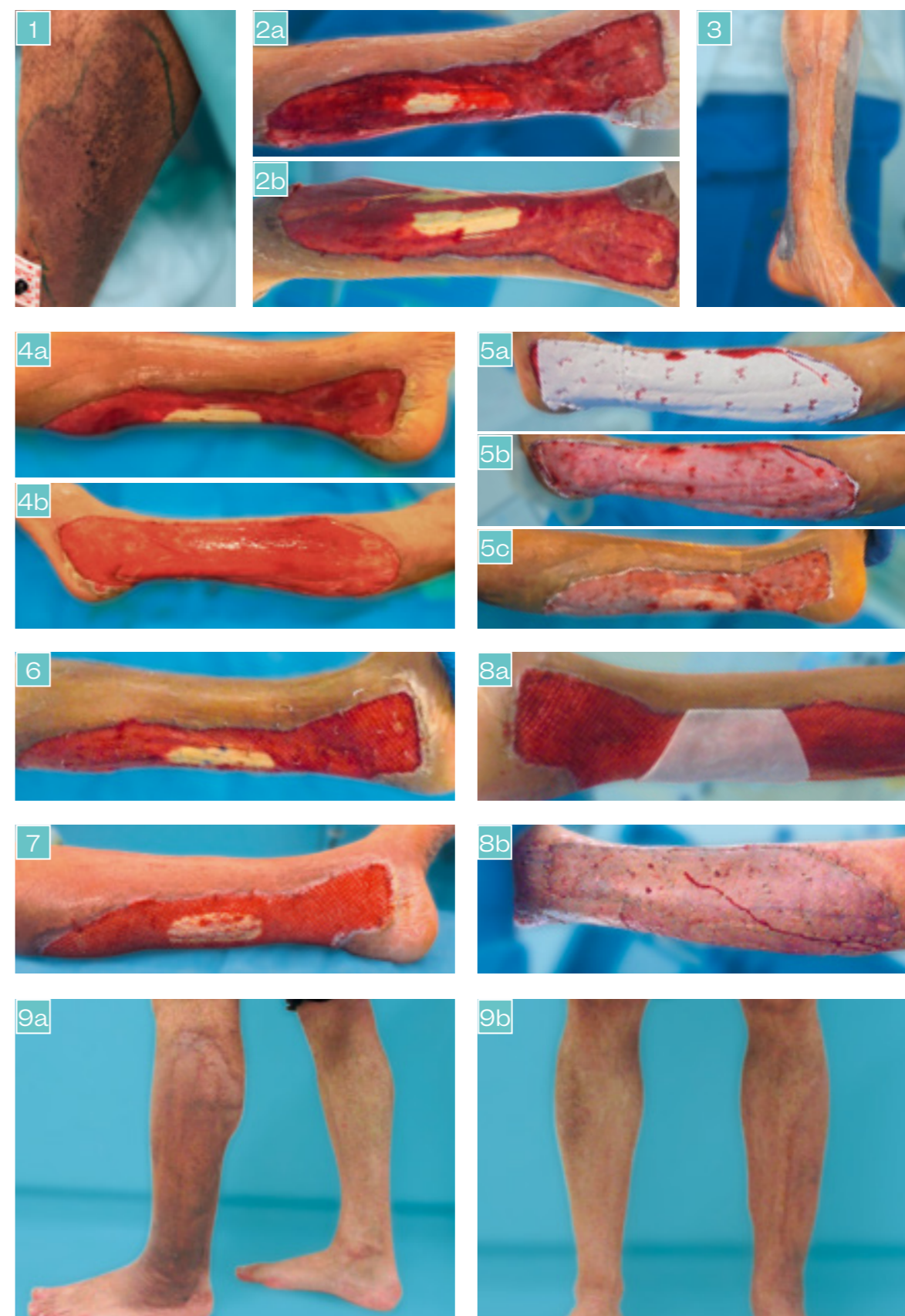


This patient who is an Orthopedic Surgeon underwent emergency debridement for necrotizing fasciitis of the lower leg (Fig.1). In order to save his leg and life almost all the skin, soft tissue and fascia of his lower leg were debrided including the vascular (paratenon layer) of the medial and lateral gastrocnemius tendons (Fig.2a-b).

NPWT with instillation and dwell time (NPWTi-d) (Fig.3) was applied following debridement for further cleansing of the wound and to form a layer of granulation tissue over the musculature producing a smoother and more even wound bed surface prior to the application of the dermal template (Fig.4a-b)

Following this a Two-Step Procedure was used by bolstering two A4 size 2mm MatriDerm® templates with NPWT and a non-adherent silicon interface layer with the aim of obliterating the soft tissue cavity which was greater than 5mm. The MatriDerm® template was also used to bridge the exposed gastrocnemius tendons (Fig.5a-c). The first NPWT dressing change showed good integration of MatriDerm® (Fig.6). After several changes of NPWT filling of the soft tissue defect was achieved with reduced area of exposed tendons lacking paratenon (Fig.7). To bridge the remaining area of tendons which lacked vascularity a smaller size 1mm MatriDerm® was applied as a One-Step Procedure with a Split-Thickness Skin Graft at the same time that was bolstered with NPWT (Fig.8a-b).

Two years postoperatively, the reconstruction of this lower leg with Two-Step Procedure 2mm and One-Step Procedure 1mm MatriDerm® shows no soft tissue indentation with intact and stable skin over the tendons with full return to function (Fig.9. a-b). The patient has returned to work as a full time Orthopedic Surgeon.



* Courtesy of I. Younis, MBBCh, MRCS (Eng), MSc, FRCS (Plast), London, UK

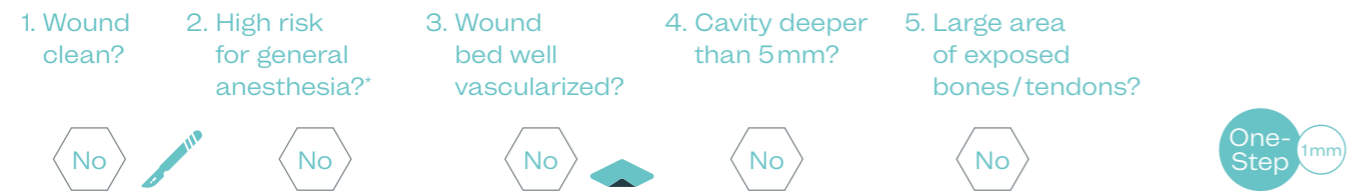Chronic venous ulcer with 3.5 years follow-up

Type of Wound Chronic venous ulcer*

Etiology Venous insufficiency with 5-year open wound on the medial and lateral side of the lower left leg

Patient 51-year-old male

Decision Tree



On first examination the wound bed appeared fibrinous and was covered with a yellowish layer, but there were no signs of necrotic tissue (Fig.1). The wound bed was treated with non-adherent gauze for 6 months prior to surgery. Antibiotics were administered and the wound was cleansed once with chlorhexidine.

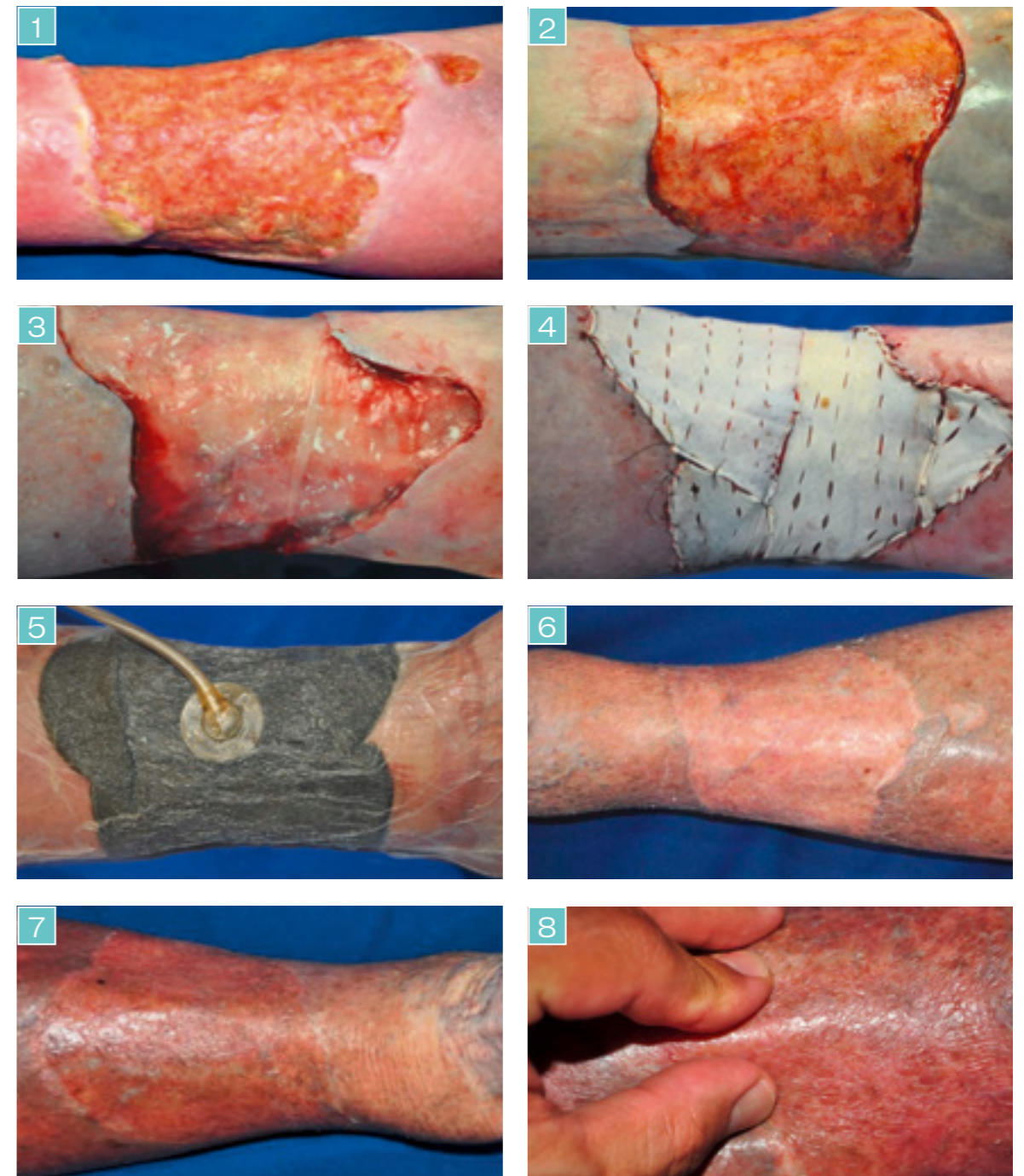
During the surgery the wound bed was properly debrided (Fig.2) prior to dry application of 1mm MatriDerm®. The matrix was rehydrated inside the wound bed (Fig.3). MatriDerm® was covered in a One-Step Procedure with a 0.010 inch, unmeshed, fenestrated split-thickness skin graft (STSG) (Fig.4).

MatriDerm® and the STSG were fixated with 6 layers of fatty gauze and V.A.C. therapy with the GranuFoam dressing was applied for 5 days (100mmHg, continuous negative pressure) (Fig.5).

At 14 days p. o.the take rate of the STSG was 95% and at 1 month the skin graft was completely integrated with full and stable wound closure, and the patient was able to wear compression socks for his venous insufficiency.

3.5 years follow-up showed very stable wound closure with good aesthetic outcome. The wound edges are leveled with the surrounding healthy tissue (Fig.6) and the patient has full functional results with extension and flexion of his leg (Fig.7, flexion). Excellent wound elasticity and pliability was achieved (Fig.8).

Chronic Wounds



* Courtesy of F. Tostes, MD, Rio Grande do Sul, Brazil
V.A.C. therapy and GranuFoam by Kinetic Concept, Inc (KCI)

Diabetic foot syndrome with gangrene

Type of Wound Gangrene of the right foot*

Etiology Diabetic foot syndrome in an obese patient

Patient 60-year-old male

Decision Tree

1. Wound clean?
2. High risk for general anesthesia?*

Yes

Yes

One-Step 1mm

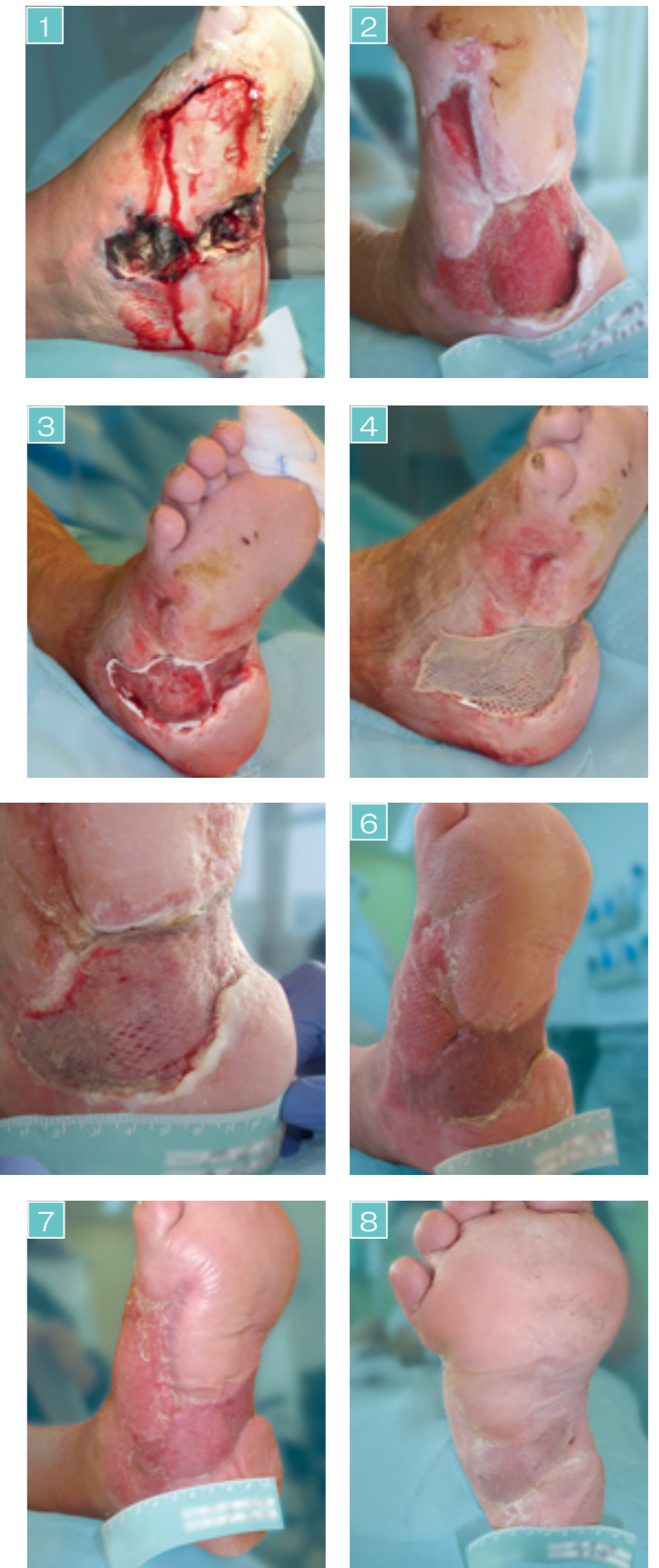A 60-year-old male with diabetic foot syndrome and a history of obesity and coronary heart disease, presented with a gangrenous right foot (Fig.1). An emergency bedside debridement was performed and IV antibiotics were started. At the following surgical debridement, the 5th metatarsal bone was resected. The wound was further debrided with the use of maggots. The wound bed was prepared with gauze-based Negative Pressure Wound Therapy (NPWT), which was set at 120 mmHg (Fig.2).

At the time of wound closure, the excess granulation tissue was removed and a dry sheet of 1mm MatriDerm® was applied on the wound bed. MatriDerm® was then moistened with Ringer's lactate (Fig.3). A split-thickness skin graft immediately followed in a One-Step Procedure (Fig.4).

A non-adherent wound contact layer was placed over the skin graft and the graft was fixated with NPWT. After 7 days, NPWT was ceased and the skin graft demonstrated good take rate and healing (Fig.5).The wound was dressed with fatty gauze dressings.

Two months post-operatively, wound healing had progressed well (Fig.6). Three and six months p. o., the wound showed stable wound closure and the patient was able to walk with a diabetic shoe (Fig.7, 8).

Chronic Wounds



* Courtesy of D. Luedi, MD, Langenthal, Switzerland

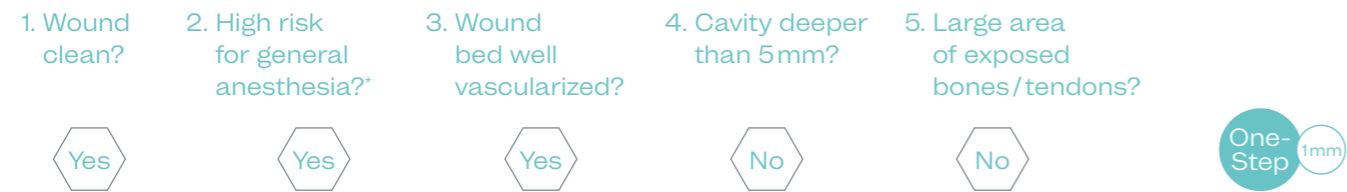
Chronic diabetic ulcer at clubfoot

Type of Wound Chronic diabetic foot ulcer*

Etiology Neuropathic cavoid foot; idiopathic clubfoot; chronic infected ulceration

Patient 47-year-old male

Decision Tree

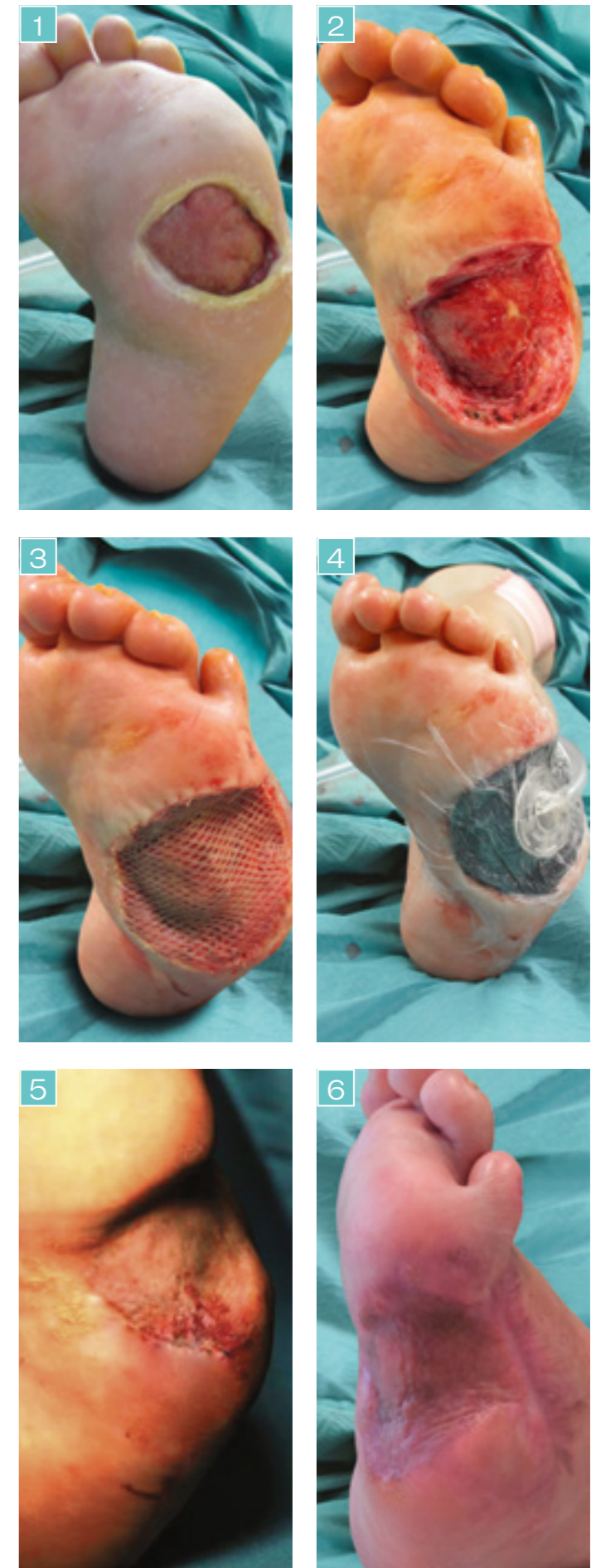

This patient with a neuropathic cavoid foot and an idiopathic clubfoot has a 4-year history of infected ulcerations on the plantar and lateral dorsal side of the foot. In the weeks prior to the reconstructive surgery, the Pseudomonas-infected ulcer was treated with MediHoney to control the infection. The wound bed was optimized with Hyiodine.

At the day of surgery, the infection was resolved and the wound size was reduced. The ulcer was thoroughly debrided resulting in a well vascularized wound bed (Fig.1,2). MatriDerm® was applied and in a One-Step Procedure covered with a meshed split-thickness skin graft which was sutured to the wound edges (Fig.3). Negative pressure wound therapy was initiated to immobilize the graft (Fig.4). At the fifth p. o. day, signs of initial graft integration were observed (Fig.5). At 6 months p. o. the wound was completely closed with good tissue elasticity and mobility (Fig.6). The patient was pain free.

* Courtesy of H. Mössner, MD, Salzburg, Austria
 Medihoney by Derma Sciences, Inc
 Hyiodine by Contipro Group s.r.o.

Chronic Wounds



Chronic mixed ulcer in diabetic patient

Type of Wound Chronic mixed ulcer of the forefoot*
Etiology Diabetic patient with mixed ulcers repeatedly covered with split skin
Patient 70-year-old patient

Decision Tree

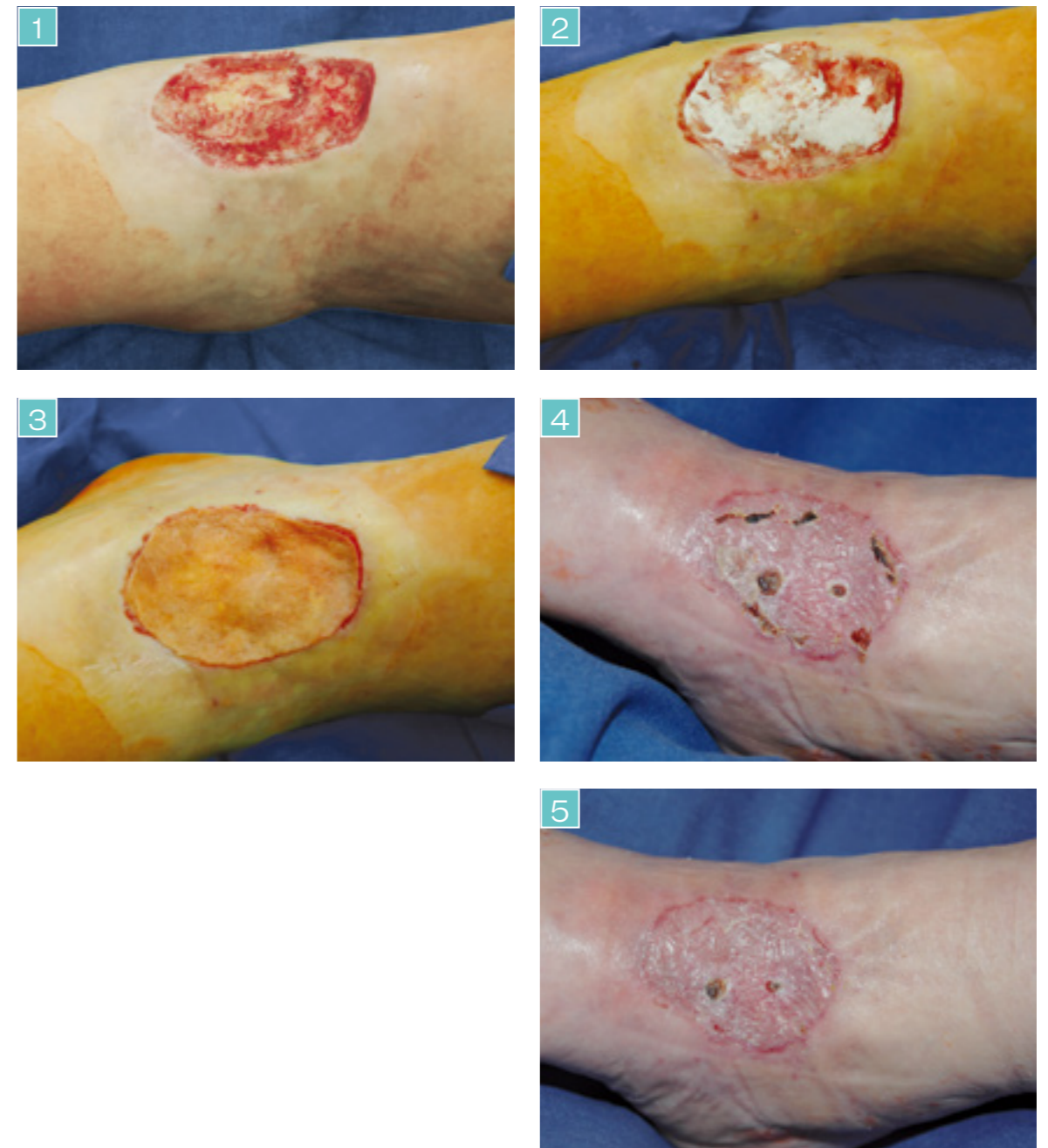1. Wound clean?
2. High risk for general anesthesia?*



The 70-year-old patient suffers from a mixed chronic ulcers. The wound bed was debrided and conditioned for 2-3 weeks (Fig.1).

Afterwards 1mm MatriDerm® was applied in a One-Step Procedure (Fig. 2) with unmeshed split-thickness skin on top of the matrix (Fig.3). After fixation with a vacuum system the wound was closed in 1 week after the surgical procedure (Fig.4). Fig.5 shows a stable result already in week 2 p. o.

Chronic Wounds



* Courtesy of M. Öhlbauer, MD, Murnau, Germany

Large pressure ulcer after an ischaemic stroke

Type of Wound Large pressure ulcer of the left thorax and the lateral side of the left knee*

Etiology Ischaemic stroke, lying on the floor for 4 days

Patient 70-year-old male

Decision Tree

1. Wound clean?
2. High risk for general anesthesia?*

Yes

Yes

One-Step 1mm

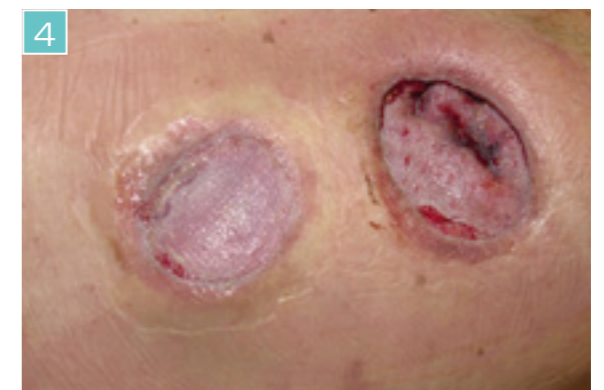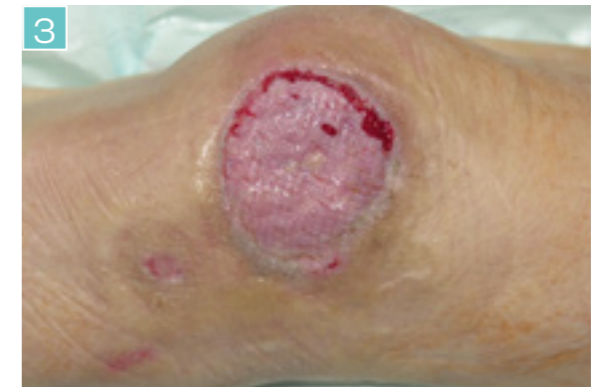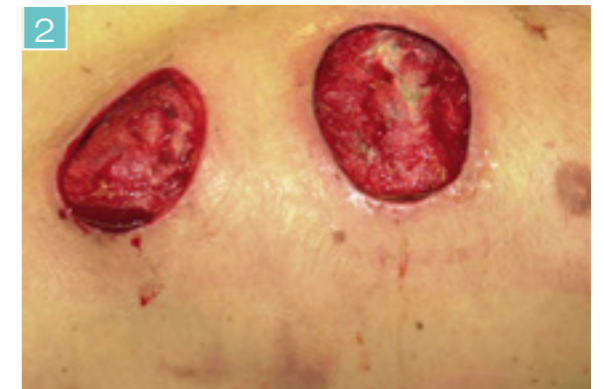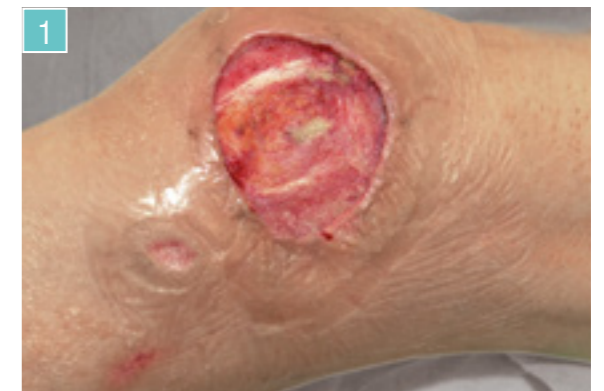A 70-year-old patient suffered from an ischaemic stroke at home. He was found 4 days later lying on the floor unable to move and had developed large pressure ulcers of the left thorax and the lateral side of the left knee. After cardiopulmonary stabilisation at the intensive care unit, operative debridement of the necrotic tissue exposed both knee capsule and rib cartilage.

Fig. 1,2 shows the left knee and left side of the thorax one week after initial debridement and the use of negative pressure wound therapy (NPWT) to obtain proper granulation of the wound beds.

Defect coverage was performed in a One-Step Procedure with 1mm MatriDerm® and unmeshed split skin grafts. NPWT was then used to encourage optimum fixation of the MatriDerm® and split-thickness skin grafts. This was discontinued after one week.

Besides optimal graft take, MatriDerm® provided reliable defect coverage (Fig. 3,4).

Chronic Wounds



* Courtesy of M. Öhlbauer, MD, Murnau, Germany

Large squamous cell carcinoma

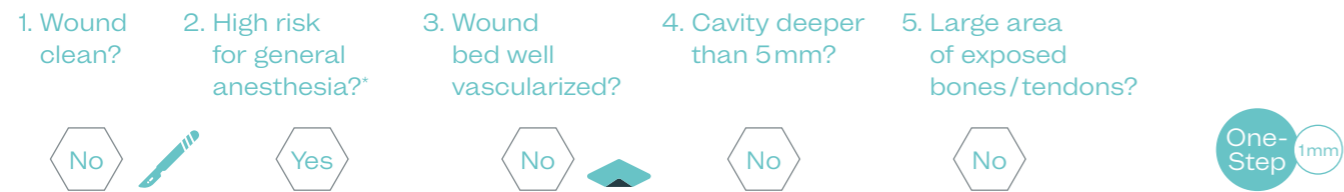Cancer Excision

Type of Wound Squamous cell carcinoma in the left popliteal fossa*

Etiology Growing ulceration of 5 years

Patient 81-year-old male

Decision Tree

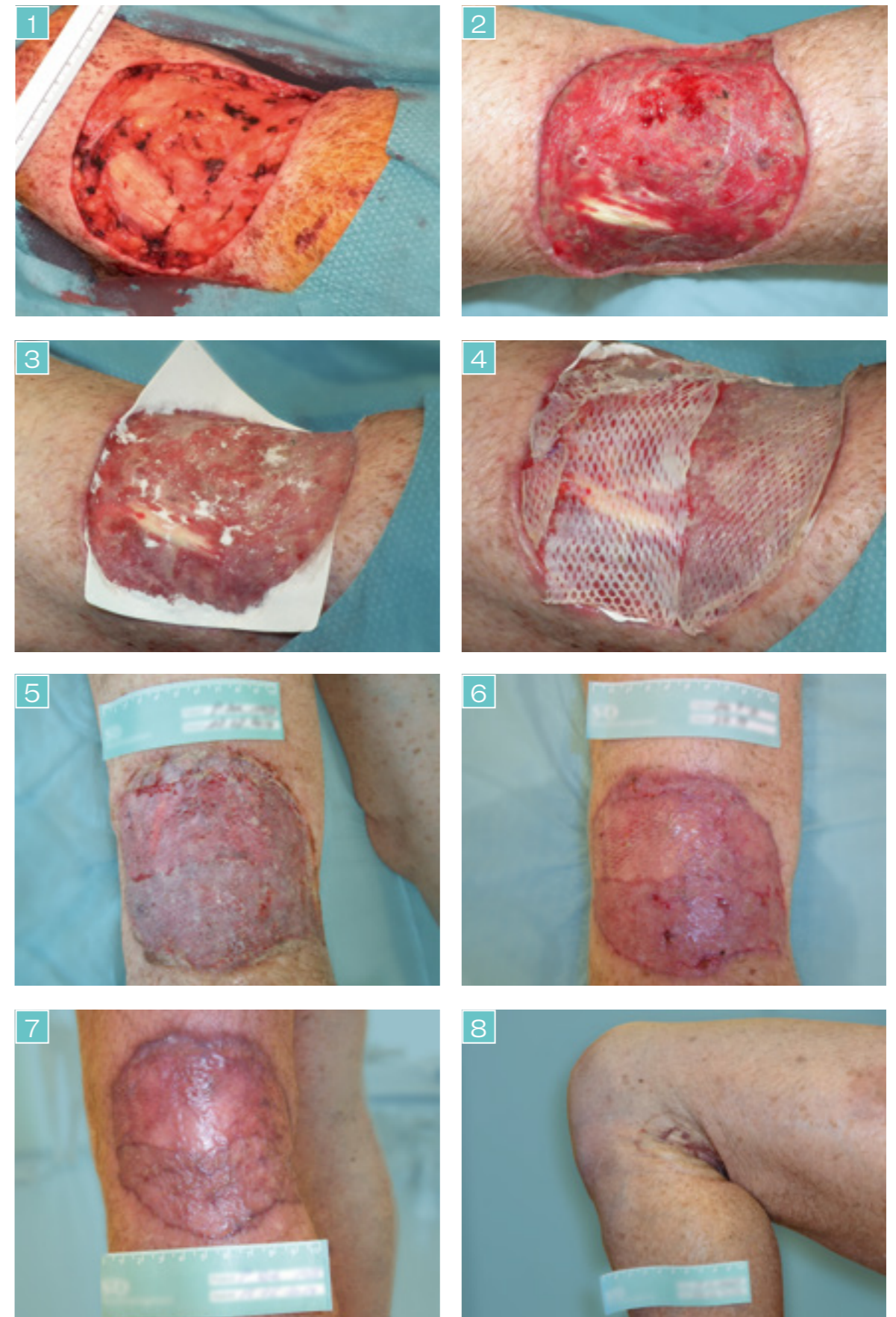

An 81-year-old male patient presented with a squamous cell carcinoma in the left popliteal fossa. The ulceration was growing already for 5 years.

The tumor was excised down to the crural fascia with a 1.5cm margin (Fig.1). Negative Pressure Wound Therapy (NPWT) was initiated to prepare the wound for closure. Two weeks after the tumor excision, the wound showed a healthy granulated wound bed (Fig.2). At the following surgical procedure, the wound was refreshed and a dry sheet of 1mm MatriDerm® was placed on the wound bed and moistened with Ringer's lactate (Fig.3). MatriDerm® was then trimmed to fit the wound edges. A 0.3mm split-thickness skin graft was positioned on top of MatriDerm® in a One-Step Procedure (Fig.4). NPWT was used for 5 days to fixate the graft. At the time of the NPWT dressing removal, the wound bed showed good signs of early healing progression (Fig.5). The wound was dressed with a fatty gauze dressing as well as local foam compression and the knee was immobilized for 2 weeks.

At the follow-up visits, the wound showed stable wound healing (Fig.6: 1 month, Fig. 7: 3 months).

At 9 months, the wound was still closed and stable, with full functional capacity (Fig.8). The patient was highly satisfied without any functional deficit or discomfort.



* Courtesy of D. Luedi, MD, Langenthal, Switzerland

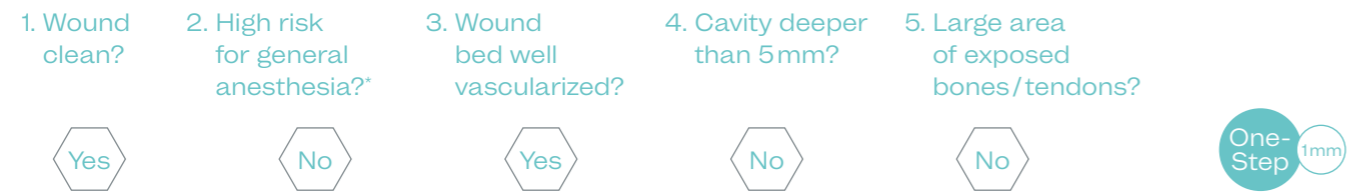Basal cell carcinoma excision in face

Type of Wound Surgical full-thickness wound*

Etiology Basal cell carcinoma

Patient 42-year-old female

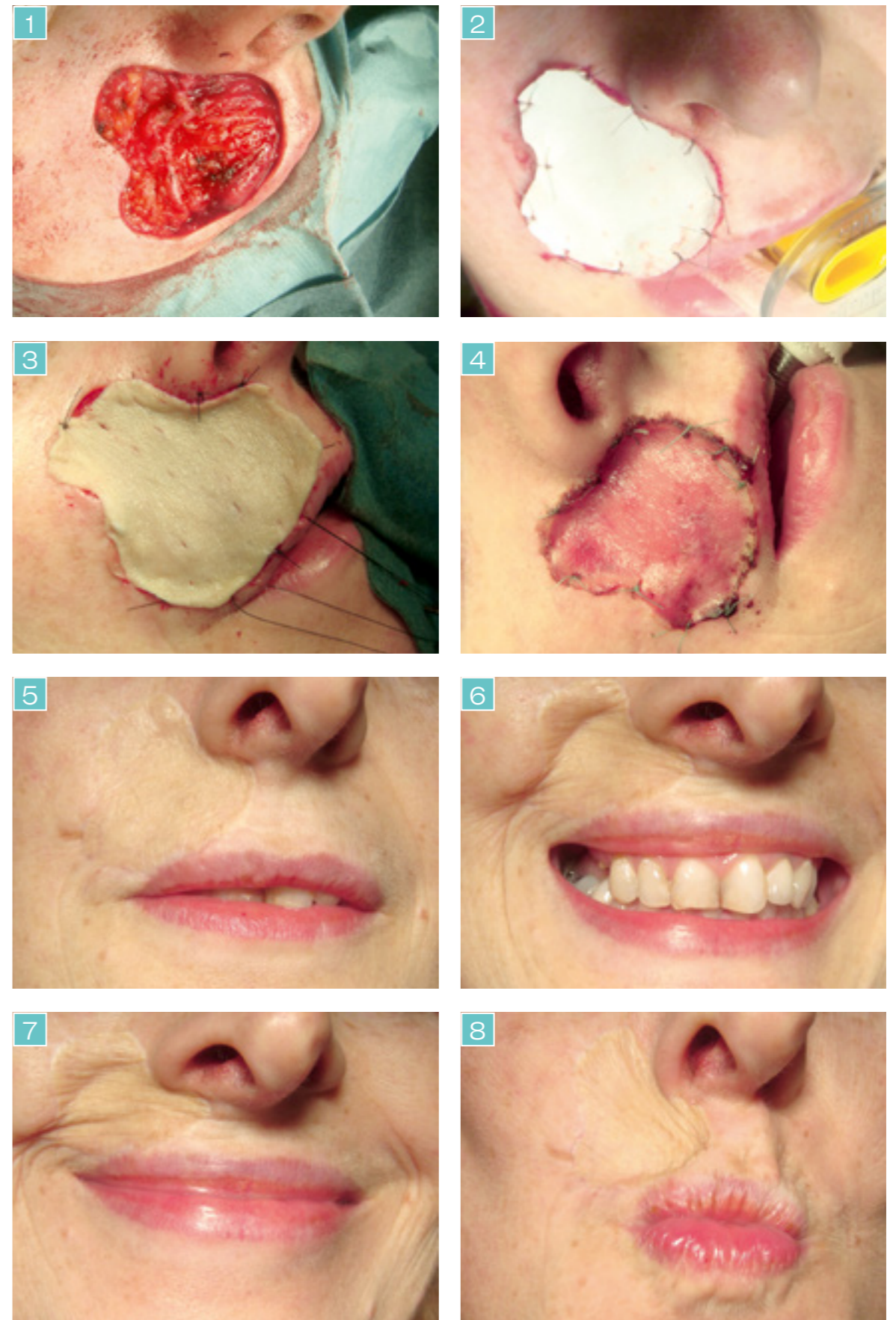
Decision Tree



Day 0: RO-excision of the carcinoma (Fig.1). The intra-operative view showing the dry application of 1mm MatriDerm® on the wound bed fixed with normal sutures (Fig.2). Immediate coverage of MatriDerm® with a fenestrated split-thickness skin graft in a One-Step Procedure (Fig.3). Afterwards the wound dressing was performed by using fatty gauze, bulky dressing and tight bandaging.

Day 14 p. o.: The post-operative view shows a complete wound closure with a full graft take of the transplant (Fig.4). Follow-up 7 months: The reconstructed skin demonstrated excellent elasticity and pliability, characteristics seen by the facial movement of this skin region (Fig.5-8). The surgeon as well as the patient were satisfied with the functional and aesthetic outcome in this special body region.

Cancer Excision



* Courtesy of N. Lilgenau, MD, Vienna, Austria

Carcinoma resection in 97-year-old patient

Type of Wound Resection of squamous cell carcinoma*

Etiology Fungating spalioma cranium

Patient 97-year-old male

Decision Tree

1. Wound clean?
2. High risk for general anesthesia?*

Yes

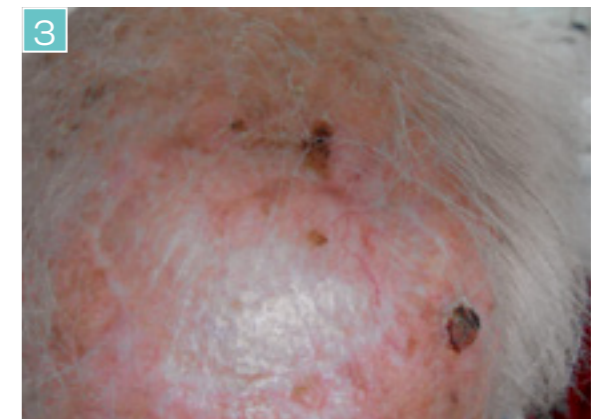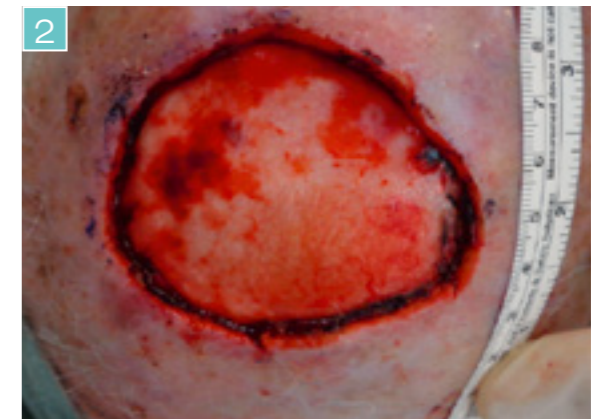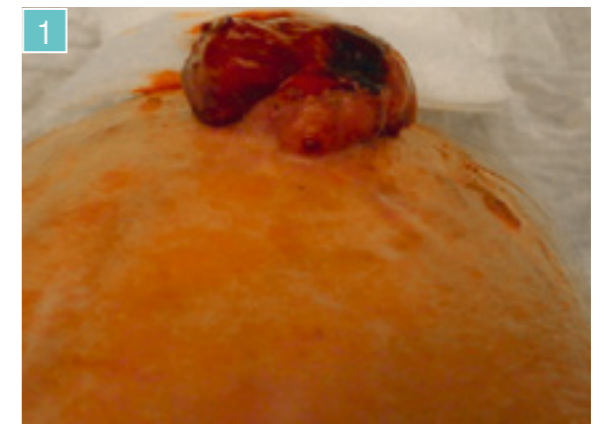Yes

One-Step 1mm

This 97-year-old patient, with a history of diabetes type II, presented with a fungating spalioma on the cranium (Fig.1). One day pre-operatively the lesion was covered with a betadine dressing.

A wide resection of the carcinoma with a 2cm safety margin was performed. This resulted in a 6 x 7cm defect on the frontal side of the cranium (Fig.2). Subsequently MatriDerm® and a split-thickness skin graft were applied on the defect in a One-Step Procedure. The surgical site was dressed with vaseline gauze and foam dressing, which were left in place for 5 days. At 1 week p. o. a 85% take rate of the skin graft was observed, and 2 months p.o. the take rate was 100%. At the follow-up visit after one year complete healing was observed with an excellent aesthetic result (Fig.3).

Cancer Excision



* Courtesy of V. Wedler, MD, Frauenfeld, Switzerland

Melanoma on the nasal ridge

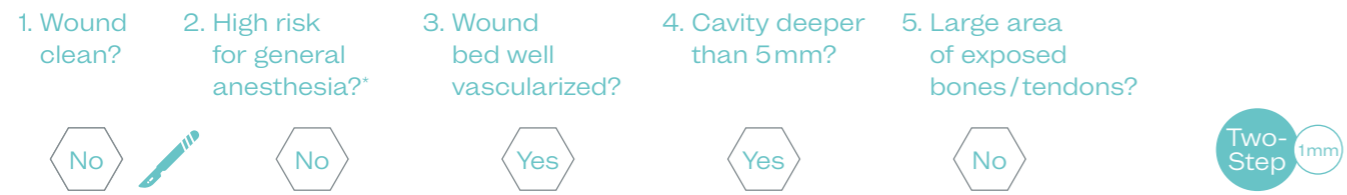
Cancer Excision

Type of Wound Resection of melanoma on the nasal ridge*

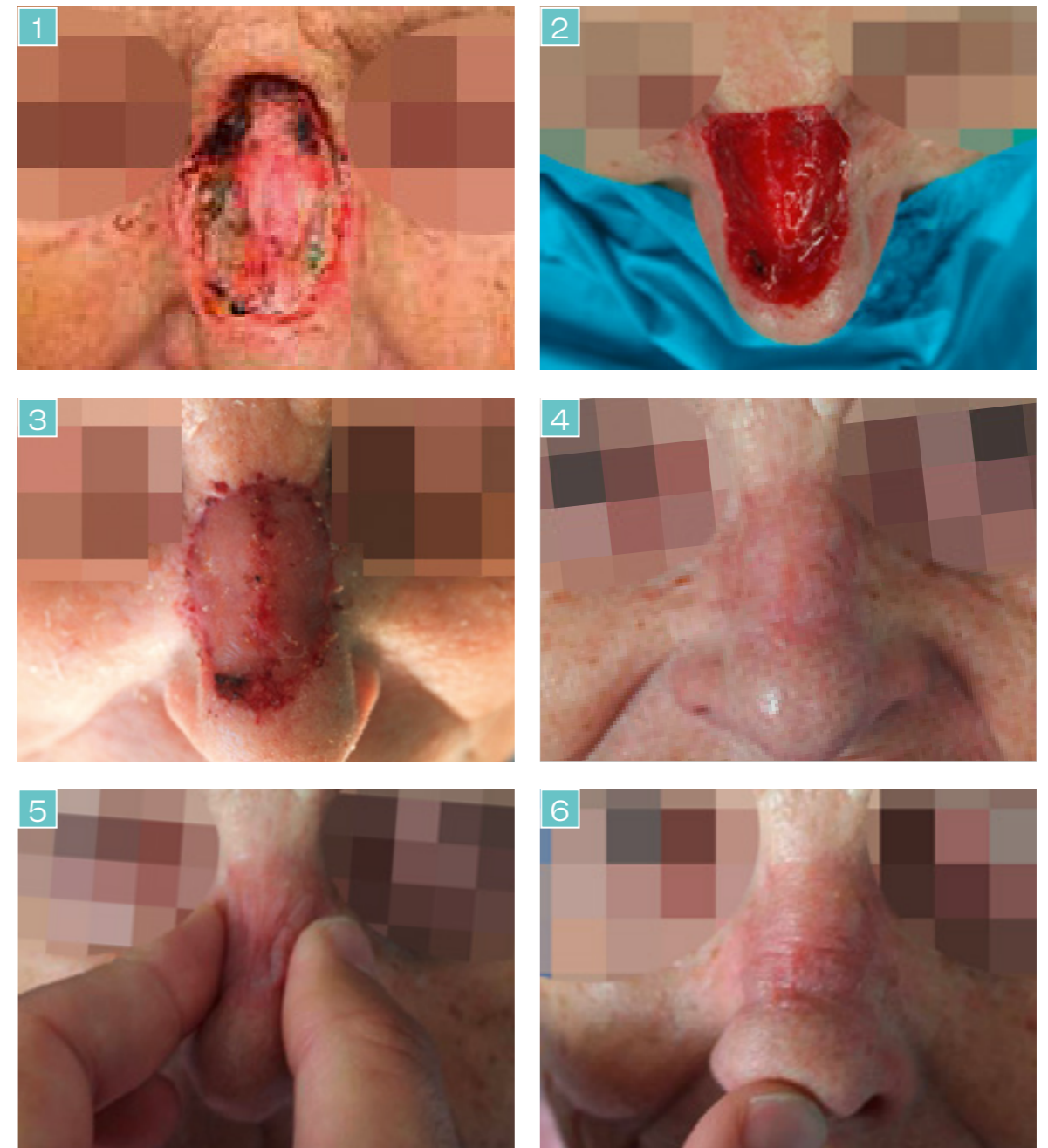Etiology Melanoma on the nasal ridge

Patient 72-year-old female

Decision Tree



The cancer was excised widely, resulting in a deep dermal wound down to the cartilage (Fig.1 one week after excision). After debridement of the wound 1mm MatriDerm® was applied to the wound bed and trimmed appropriately. 10 days after MatriDerm® application (Fig.2) the wound was grafted with skin grafts from both upper eyelids because of similar skin texture to the nasal ridge. Short-term follow-up (Fig.3) shows viable skin graft with typical pink appearance. At long-term follow-up (Fig.4) the grafted area showed similar skin color as the surrounding skin with a very good skin elasticity (Fig.5 and 6).



* Courtesy of M. Öhlbauer, MD, Murnau, Germany

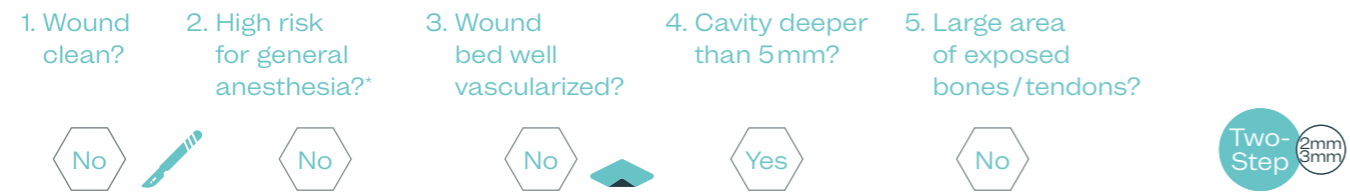Malignant melanoma on plantar foot

Type of Wound Plantar foot wound not requiring skin graft*

Etiology Post wide excision of malignant melanoma

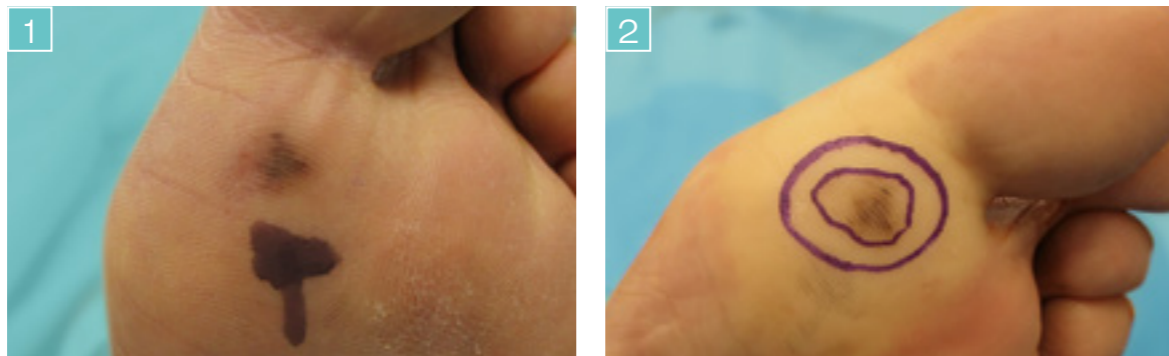Patient 26-year-old male

Decision Tree

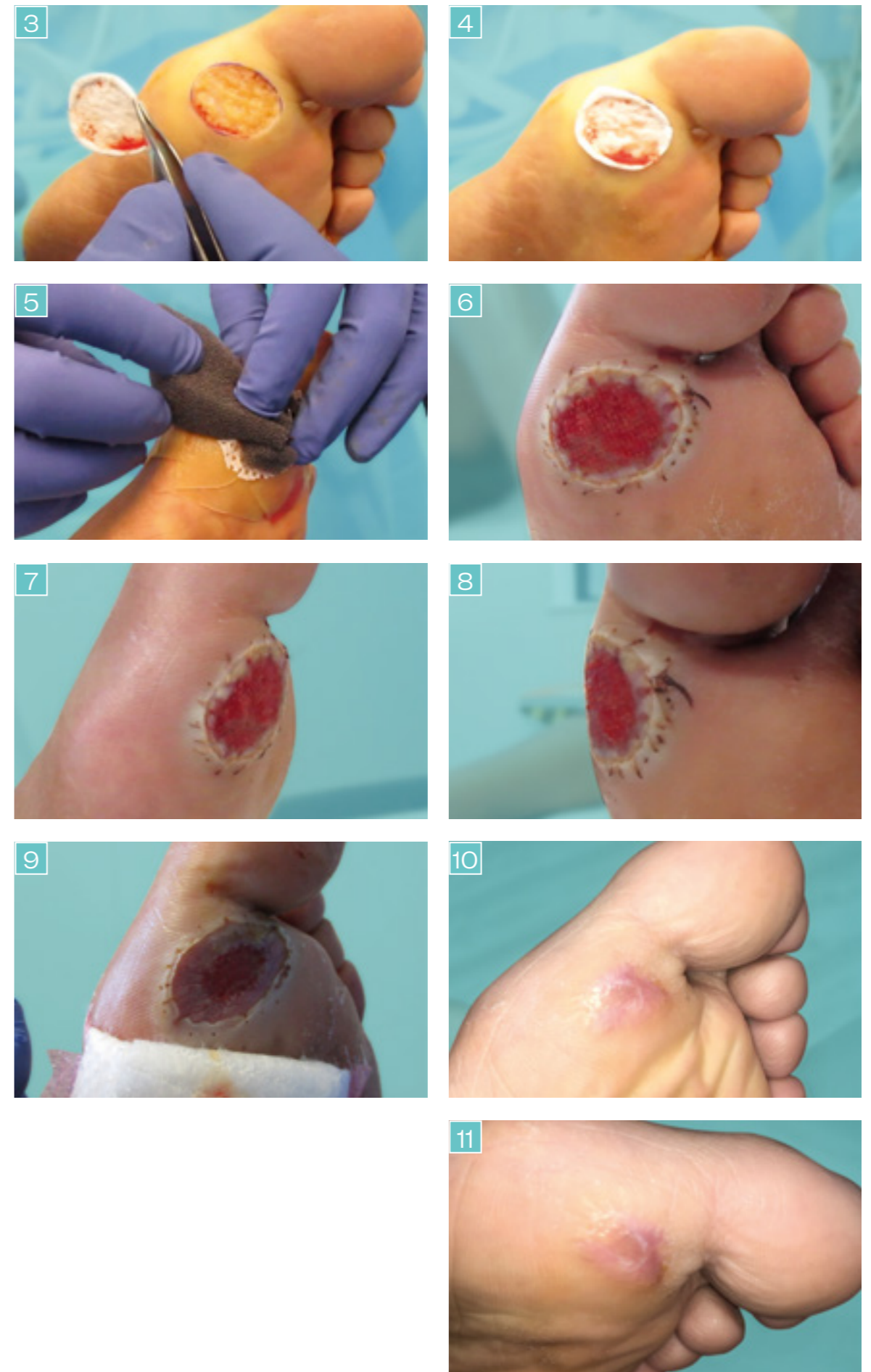

This patient had a malignant melanoma in situ (pre skin cancer) on a pressure bearing area of the plantar surface of his foot (Fig.1). He underwent a 5mm wide local excision to complete his surgical treatment (Fig.2). This left a 3cm wide circular defect with exposed poorly vascularised subcutaneous fat (Fig.3). Rather than undertake a split thickness skin graft on a poorly vascularised wound bed with a significant risk of poor take and contour defect, 2mm MatriDerm® was applied (Fig.4). This was secured with quick dissolving sutures and the surrounding skin protected with hydrocolloid before applying negative pressure wound therapy at -125mm of Hg (Fig.5) to reduce shearing, increase stability and aid the integration of the MatriDerm®. He was advised not to bear weight on this area for two weeks. The plan was to undertake a split thickness skin graft from the 'instep' area of the plantar surface of the same foot as this has pressure bearing properties as a two step technique.

After 14 days post surgery MatriDerm® had not only integrated well but interestingly the peripheral 5mm had started epithelialising (Fig.6-7) with no contour defect (Fig.8). At 21 days there was further progression of epithelialisation centrally (Fig.9). As over 50% of the MatriDerm® had epithelialised really well, we saw no reason to undertake a split thickness graft. At six weeks post surgery the wound had not only fully epithelialised but had remodelled with no tethering, instability or contour defect (Fig.10-11). The patient was able to fully weight bear and undertake all normal every activities including sports such as football.



Cancer Excision



* Courtesy of I. Younis, MBBCh, MRCS (Eng), MSc, FRCS (Plast), London, UK

Adherent scar after extravasation of cytotoxic drugs

Type of Wound Adherent scar after extravasation of cytotoxic drugs*

Etiology Adherent scar over the flexor tendon of the hand after extravasation of cytostatics

Patient 57-year-old female

Decision Tree

Note: MatriDerm® is used as adhesion barrier and therefore no recommendation from the Decision Tree is needed

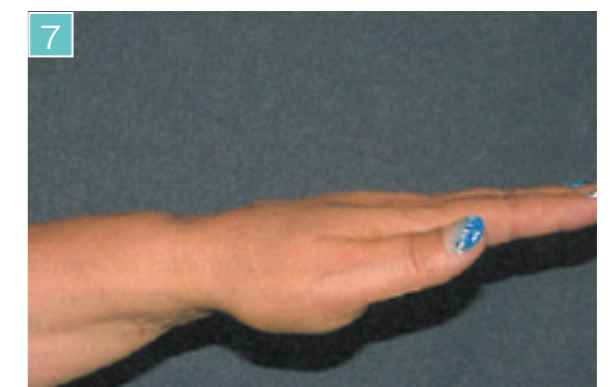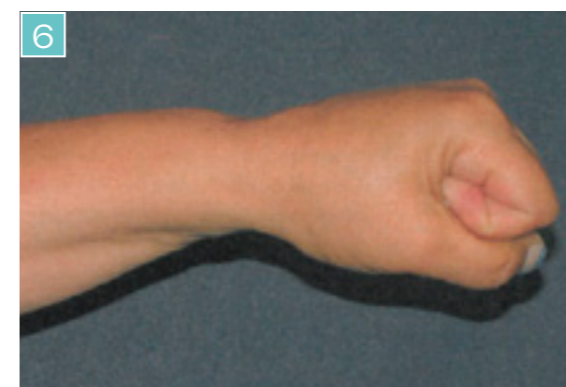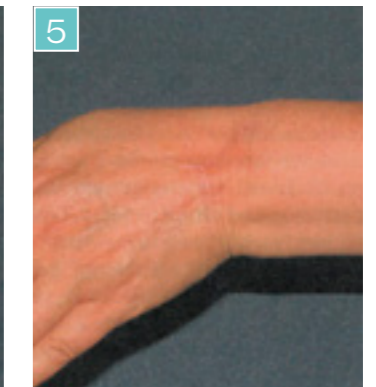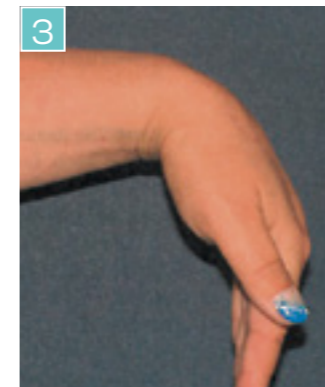
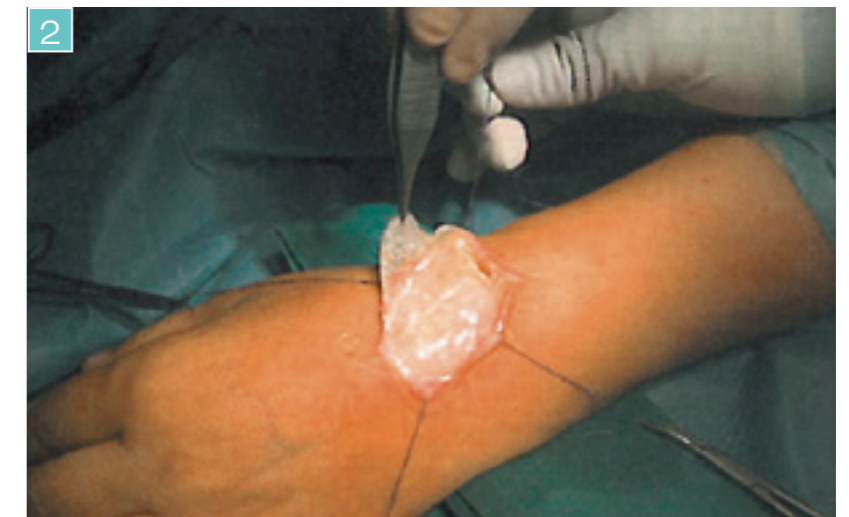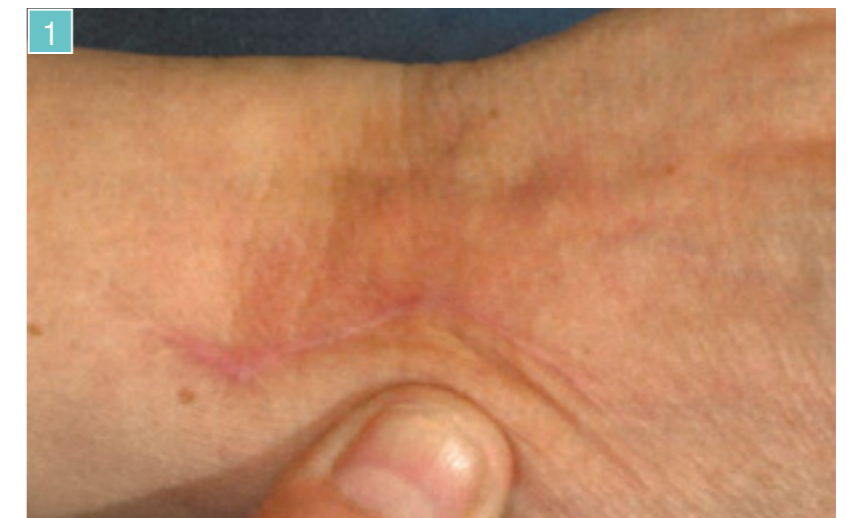As a side-effect of chemotherapy for breast cancer treatment in 2001, extravasation led to tissue necrosis on the back of the hand. The resulting adherent scar limited hand movement and caused pain. A release of the scar tissue and a tenolysis of the extensor tendon performed in 2002 did not improve pain and mobility.

Pre-operative view: A 4 cm long scar on the back of the hand with 5 cm wide atrophic and hyperpigmented skin around it. The skin had adhered to the underlying tissue and was not movable (Fig. 1). There was a marked limitation in flexion and extension mobility (Range of Motion: Flexion 40°, extension 30°), and ulnar and radial abduction (Range of Motion: Ulnar 25°, radial 5°).

After careful detachment of the skin from the tendons, a 1 mm rehydrated sheet of MatriDerm® was inserted between the layers (Fig. 2). An intra-cutaneous continuous suture was used for closure.

Post-operatively the wound site showed good vascularization without irritation. One year p. o. the patient is completely complaint-free with good movement of the skin over the underlying tissue. There is complete mobility of the hand (Range of Motion: Flexion 80°, extension 90°, ulnar 40°, radial 38°, (Fig. 3–5). The patient can clench her fist without any problems (Fig. 6) and can fully extend the hand (Fig. 7). The patient is very satisfied with the functional and aesthetic result.

Adhesion Barrier



* From Keck et al. 2008, Handchir Mikrochir Plast Chir; ©Thieme

Treatment of adherent foot tendon

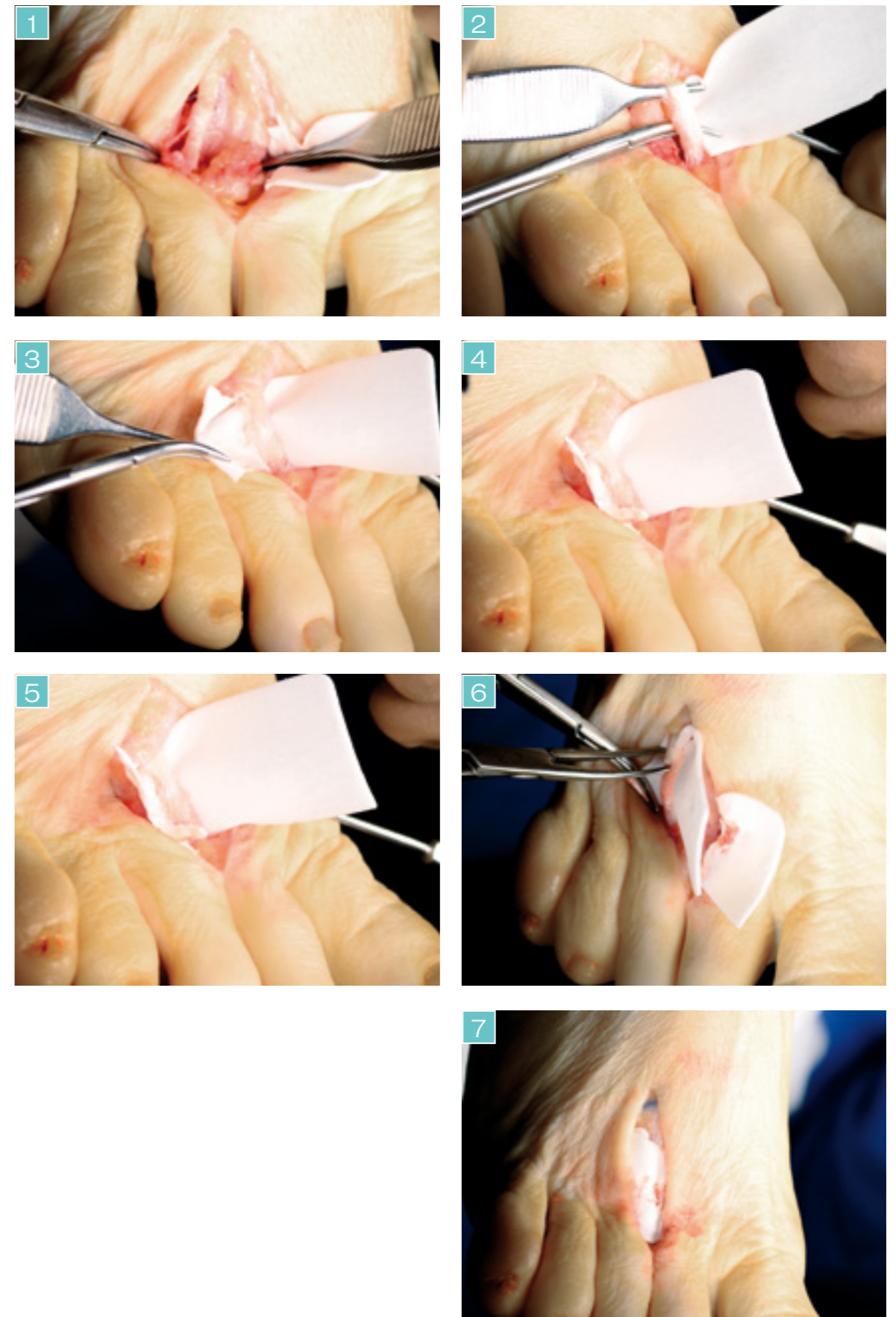
Type of Wound Tenolysis*
Etiology Tendon adhesion after foot surgery
Patient 63-year-old patient

Decision Tree

Note: MatriDerm® is used as adhesion barrier and therefore no recommendation from the Decision Tree is needed

Surgical approach at the musculus flexor digitorum brevis. Preparation and release of the adhesive tissue (Fig.1). Gentle pull through of a small sheet of dry 1mm MatriDerm® (Fig.2-5). Wrapping of the tendon (Fig.6). Final view before wound closure (Fig. 7). No reoccurrence of the claw toe and the patient no longer has an incorrect position and is able to wear his own shoes.

Adhesion Barrier



* Courtesy of U. Graf, MD, Zurich, Switzerland

Adherent scar at knee

| | |
|----------------------|--|
| Type of Wound | Adherent scar at knee* |
| Etiology | Tear of cruciate ligament with adhesions |
| Patient | 30-year-old female |

Decision Tree

Note: MatriDerm® is used as adhesion barrier and therefore no recommendation from the Decision Tree is needed

A 30-year-old female patient presented with a painful scar with adhesions and limited movement after a torn cruciate ligament of the left knee. After refixation of the ligament with a titanium screw followed by several revision surgeries due to infection, adhesions had developed (Fig.1).

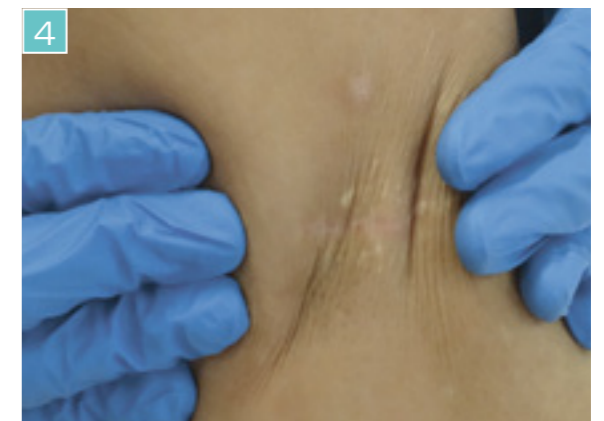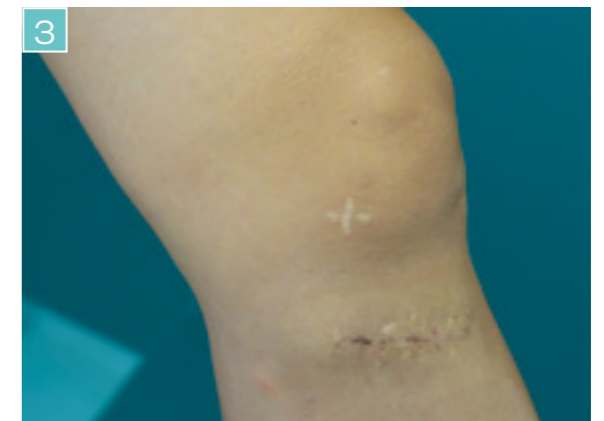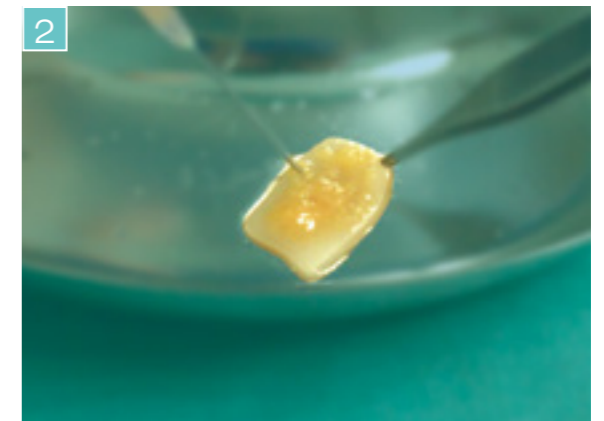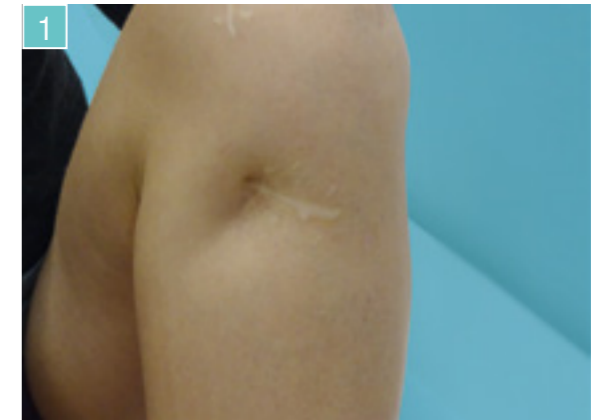In the release procedure, the scar was excised, and adhesiolysis was performed of the altered subcutaneous tissues up to the periost in the region of the implanted titanium screw. Two 2x4cm 2mm sheets of MatriDerm® protective matrix were placed in between the epiperiosteal and subcutaneous space, in order to prevent further adhesions. Directly on top of the rehydrated MatriDerm®, as well as in the subcutaneous tissue, fat cells were transferred that were gained with lipo-aspiration (Fig.2).

The wound was sutured and covered with sterile wound dressings. Increased load bearing was initiated 2 weeks post-operatively.

One week post-operatively, the patient indicated a marked improvement in pain complaints. Three weeks post-operatively the sutures were removed and the wound showed good aesthetic result (Fig.3). The patient reported virtually no pain and was able to fully bend the knee.

Three months post-operatively, the patient was able to put full load bearing on the knee and was free of complaints. The skin demonstrated excellent pliability (Fig.4). This case demonstrates the successful use of MatriDerm® as a protective matrix for prevention of recurrent adhesions.

Adhesion Barrier



* Courtesy of W. Meyer, MD, Fort Malakoff Clinic, Mainz, Germany

Exposed tendon of the hand

Type of Wound Soft tissue defect with exposed tendon*

Etiology Squamous cell carcinoma on dorsum of left hand

Patient 80-year-old female

Decision Tree

- 1. Wound clean?
- 2. High risk for general anesthesia?*

Yes

Yes

One-Step 1mm

An 80-year-old patient with a history of hypertension, was referred with a suspicious lesion on the dorsum of the left hand, which was confirmed to be a squamous cell carcinoma by histopathological examination.

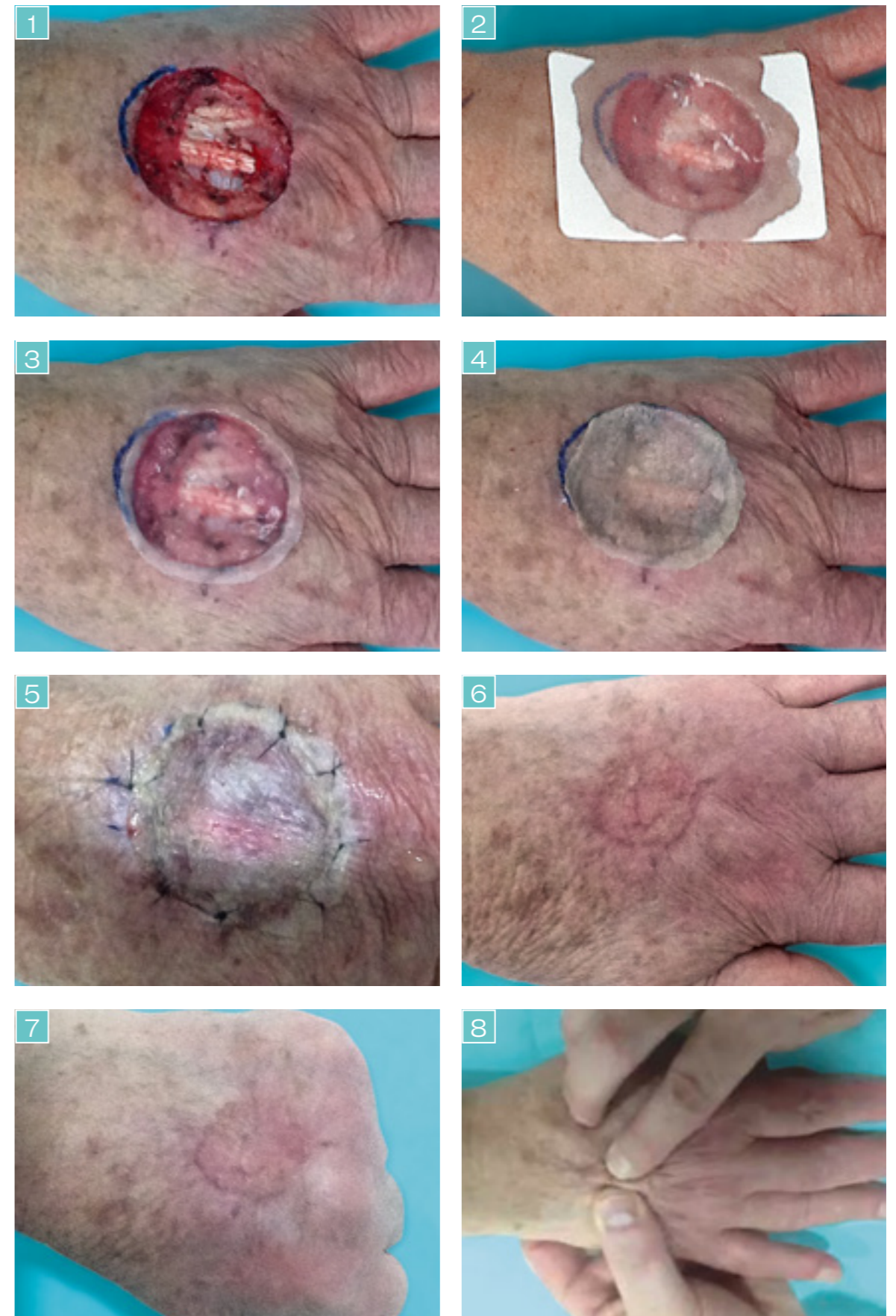The 2 x 2 cm tumor lesion was excised with appropriate margins. The wound bed was carefully debrided, which resulted in a defect with exposed tendons (Fig. 1).

The defect was covered with a 1mm dry sheet of MatriDerm® which was rehydrated in situ (Fig. 2). MatriDerm® was then cut to fit the wound bed with a 2mm margin (Fig. 3). A split-thickness skin graft (STSG) was then placed on top of MatriDerm® in a One-Step Procedure (Fig 4). The STSG was fixated using sutures.

The wound was dressed with 4 layers of non-adherent gauze, 5 layers of bulky dressing and was fixed with tight bandaging. Appropriate immobilization was ensured.

The first dressing change was performed on the 8th day after surgery and showed a stable wound bed and an excellent take rate of the graft (Fig. 5). Fifteen days post-operatively the wound was closed completely without any signs of breakdown. At 3 month follow-up the wound was healed completely with excellent pliability and full range of motion without tendon adhesions (Fig. 6-8). There was no need for further surgeries.

Adhesion Barrier



* Courtesy of J. Federbusch, MD, Rio Grande do Sul, Brazil

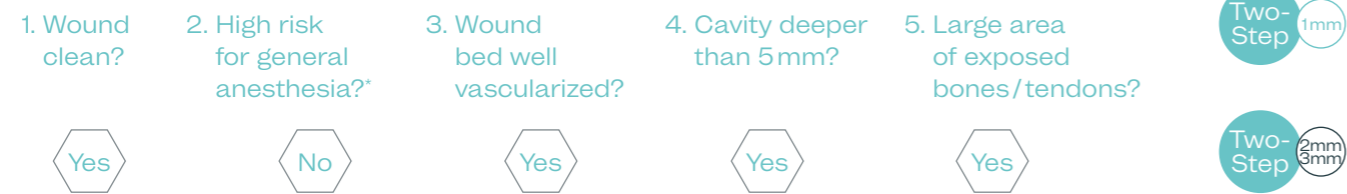
Donor Site after Phalloplasty with the Radial Forearm Flap

Type of Wound Donor site*

Etiology Phalloplasty with the radial forearm free flap (RFFF) is associated with a large donor site defect

Patient female-to-male transgender patient

Decision Tree



NOTE**

Consecutive patient underwent female-to-male affirming surgery. On the preoperative day, the flap was drawn on the non-dominant hand and an Allen test was performed to confirm vascular support from the ulnar artery. Under a tourniquet, the flap was raised distally to proximally and care was taken to meticulously clip all vessel branches. The radial sensory nerve (asterisk Fig. 1) was identified, dissected, and spared. The flap was raised in a subfascial plane and care was taken to include the proximal sensory nerves, veins and axial pedicle.

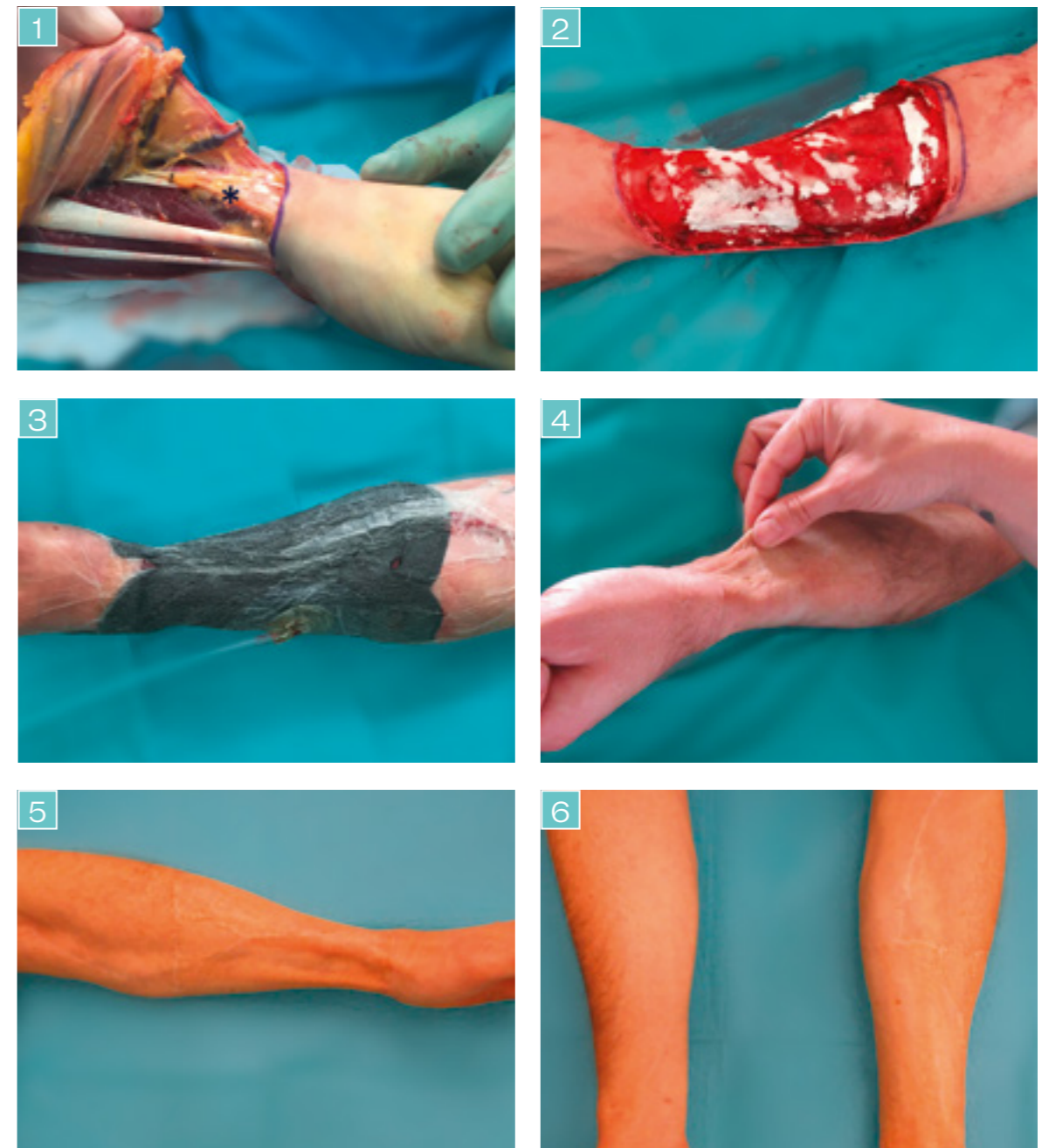
At this donor site, the flexor carpi radialis and brachioradialis muscle bellies were approximated and sutured together before skin graft coverage, providing a better recipient site for the graft. In addition, the flexor carpi radialis epitendineum was preserved to maximally support graft take.

After a meticulous haemostasis, two MatriDerm® sheets (1mm) were placed over the defect (Fig. 2). An STSG was harvested using an air dermatome of 0.2mm thickness and fibrin glue¹ was sprayed on the STSG. The STSG was directly placed over collagen elastin matrix in a one-step procedure. A vacuum-assisted closure² was applied for 1 week at continuous -125mm Hg pressure (Fig. 3).

4-year after surgery the aesthetic and functional outcome demonstrate very good parameter in sensory and functional skin texture, quality and cosmetic appearance (Fig. 7). The skin could be pinched more than 1cm (Fig. 4.)

This case shows the good sensory and functional results achieved by using MatriDerm® at the donor site after RFFF harvesting in transgender surgery.

Donor Sites



* Courtesy of W. Watfa, MD, Lausanne, Switzerland. Watfa et al., MatriDerm® Decreases Donor Site Morbidity After Radial Forearm Free Flap Harvest in Transgender Surgery, J Sex Med. 2017 Oct;14(10):1277-1284.

** The surgeon used MatriDerm® in a One-Step procedure. Upon the discretion of the surgeon and his/her experience with dermal substitutes the procedure and thickness of MatriDerm® can differ from the recommended pathway of the decision tree.

1 Artiss, Baser Healthcare Cooperation, Westlake Village, CA, USA

2 KCI, San Antonio, TX, USA


MatriDerm® Flex Dermal Matrix

A4
210 x 297 mm

| | Ref. No. | Size |
|----|-------------|-----------------|
| A4 | 83440 - 200 | 210 x 297 x 1mm |
| | 83460 - 200 | 210 x 297 x 2mm |
| | 83470 - 200 | 210 x 297 x 3mm |
| A6 | 83441 - 200 | 105 x 148 x 1mm |
| | 83461 - 200 | 105 x 148 x 2mm |
| | 83471 - 200 | 105 x 148 x 3mm |
| A8 | 83442 - 200 | 52 x 74 x 1mm |
| | 83462 - 200 | 52 x 74 x 2mm |
| | 83472 - 200 | 52 x 74 x 3mm |
| A9 | 83443 - 200 | 37 x 52 x 1mm |
| | 83463 - 200 | 37 x 52 x 2mm |
| | 83473 - 200 | 37 x 52 x 3mm |

MatriDerm® Fenestrated Dermal Matrix

| | Ref. No. | Size |
|----|-------------|-----------------|
| A4 | 83410 - 200 | 210 x 297 x 1mm |
| | 83420 - 200 | 210 x 297 x 2mm |
| | 83430 - 200 | 210 x 297 x 3mm |
| A6 | 83411 - 200 | 105 x 148 x 1mm |
| | 83421 - 200 | 105 x 148 x 2mm |
| | 83431 - 200 | 105 x 148 x 3mm |
| A8 | 83412 - 200 | 52 x 74 x 1mm |
| | 83422 - 200 | 52 x 74 x 2mm |
| | 83432 - 200 | 52 x 74 x 3mm |
| A9 | 83413 - 200 | 37 x 52 x 1mm |
| | 83423 - 200 | 37 x 52 x 2mm |
| | 83433 - 200 | 37 x 52 x 3mm |



MatriDerm® Dermal Matrix

| | Ref. No. | Size |
|----|-------------|-----------------|
| A4 | 83500 - 200 | 210 x 297 x 1mm |
| | 83400 - 200 | 210 x 297 x 2mm |
| A6 | 83403 - 200 | 105 x 148 x 1mm |
| | 83401 - 200 | 105 x 148 x 2mm |
| A8 | 83404 - 200 | 52 x 74 x 1mm |
| A9 | 83405 - 200 | 37 x 52 x 1mm |

All product and company names are trademarks [™] or registered [®] trademarks of their respective holders. Use of them does not imply any affiliation with or endorsement by them.

Please check complete indications and recommended application in your local Instructions for Use (IFU) before using MatriDerm®.